

# CASE REPORT

## Nonsurgical Treatment of a Mature Adult Class III Patient

GUDRUN LÜBBERINK, DDS, MSC  
MANUEL NIENKEMPER, DDS, MSC  
BENEDICT WILMES, DDS, MSC, PHD  
BJÖRN LUDWIG, DMD, MSD  
DIETER DRESCHER, DDS, MSC, PHD

**A**dult orthodontic treatment involves challenging biomechanical considerations, due both to the lack of skeletal growth potential and to age-related changes in biological response. An older patient often presents with some degree of mutilated dentition, necessitating alterations in treatment strategy. In addition, the risks of root resorption and periodontal complications are increased, especially over a long treatment period. Because of

these issues, as well as social and work-related pressures, adults need quick and efficient orthodontic treatment.

Skeletal anchorage has made it possible to perform complex tooth movements in situations that previously would have required surgery, such as adult patients with periodontal disease or missing teeth. Besides requiring no special compliance, mini-implants are minimally invasive, relatively affordable, and versatile.<sup>1-5</sup> This

article describes the nonsurgical treatment of a mature adult Class III patient using mini-implants for compensatory mechanics.

### Diagnosis and Treatment Plan

A 53-year-old female presented with a moderate dental and skeletal Class III malocclusion and numerous missing teeth (Fig. 1). Her profile was concave in both centric relation (CR) and



Dr. Lübberink



Dr. Nienkemper



Dr. Wilmes

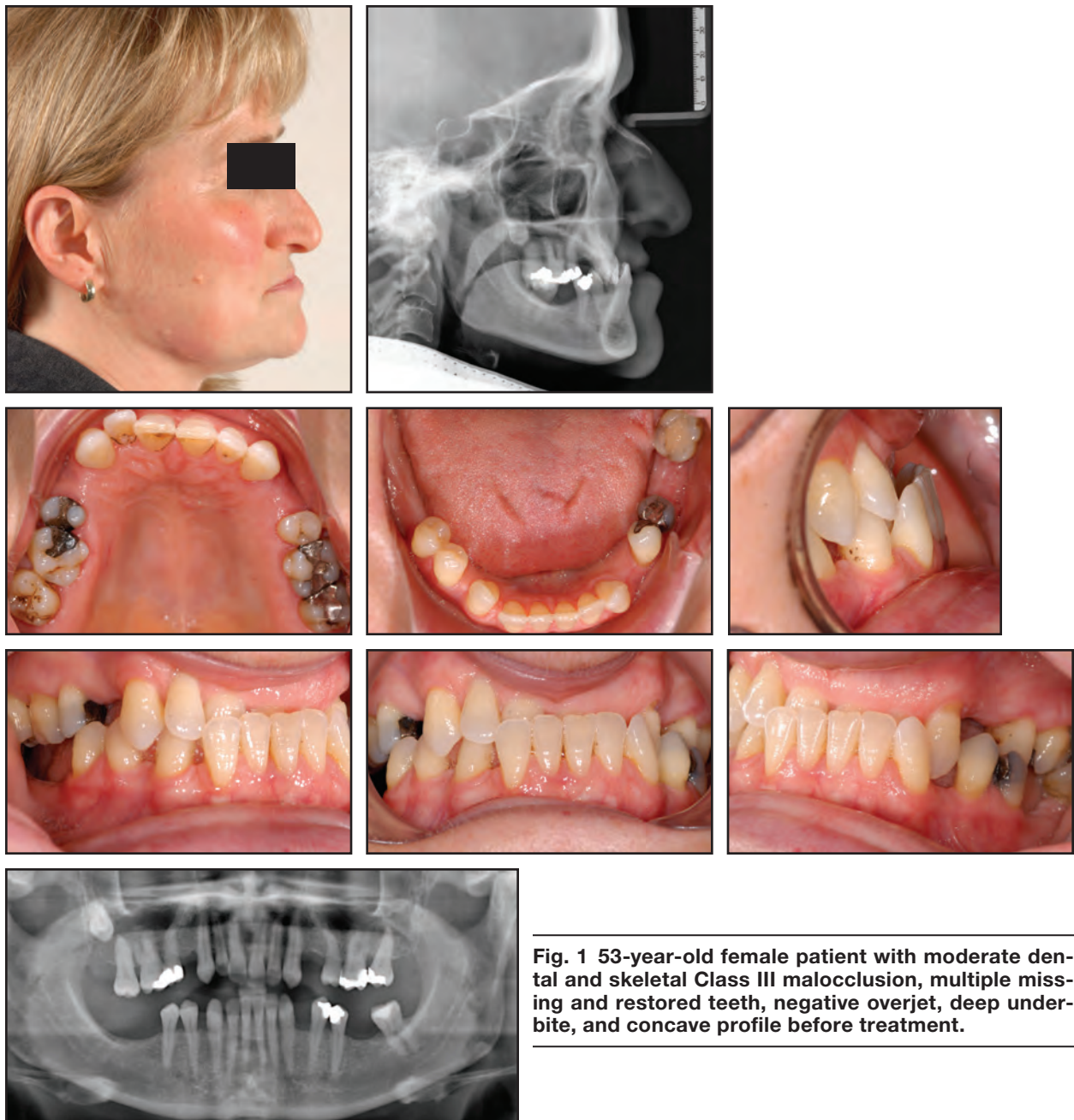


Dr. Ludwig



Dr. Drescher

Drs. Lübberink and Nienkemper are Assistant Professors, Dr. Wilmes is a Professor, and Dr. Drescher is Professor and Head, Department of Orthodontics, University of Düsseldorf, Moorenstr. 5, 40225 Düsseldorf, Germany. Dr. Wilmes is also a Visiting Professor, Department of Orthodontics, University of Alabama at Birmingham School of Dentistry, and the developer of the Benefit system. Dr. Ludwig is a Contributing Editor of the *Journal of Clinical Orthodontics*, an Instructor, Department of Orthodontics, University of Homburg, Saar, Germany, and in the private practice of orthodontics in Traben-Trarbach, Germany. E-mail Dr. Lübberink at [crystal-clear@gmx.de](mailto:crystal-clear@gmx.de).



**Fig. 1** 53-year-old female patient with moderate dental and skeletal Class III malocclusion, multiple missing and restored teeth, negative overjet, deep underbite, and concave profile before treatment.

centric occlusion (CO), and her lower lip was prominent. The facial proportions indicated a brachyfacial pattern with no significant asymmetries. Both upper first premolars were missing, as

well as the lower left first molar and the lower right first and second molars. The upper right third molar was unerupted, but the other three third molars had been extracted. Several of the remain-

ing premolars and molars were heavily restored. The incisors were in crossbite, with a -3mm overjet and a deep, 8mm underbite. The patient's oral hygiene was fair.

Cephalometric evaluation showed that the maxilla was in a normal relationship to the cranial base; in CO, the mandible was slightly protrusive relative to the cranial base (Table 1). The upper incisors were slightly retrusive, but the lower incisors were normally inclined. A Wits appraisal of  $-4.5\text{mm}$  indicated a Class III relationship, and a maxillomandibular plane angle of  $14.4^\circ$  confirmed a brachyfacial pattern.

When the patient requested nonsurgical treatment, a plan was devised that would employ skeletal anchorage to support mesialization of the upper posterior teeth. Treatment objectives included:

- Protrusion of the upper incisors.
- Slight retrusion of the lower incisors.
- Mesialization and space closure of the upper and lower buccal segments.
- Uprighting and mesialization of the lower left second molar.
- Establishment of a Class I canine relationship.
- Correction of the midline shift, overbite, and overjet.
- Correction of the lateral and anterior crossbites.
- Improvement of the patient's profile and dental esthetics.

**Treatment Progress**

Under local anesthesia, a  $2\text{mm} \times 9\text{mm}$  anterior and a  $2\text{mm} \times 11\text{mm}$  posterior Benefit\* mini-implant were inserted in the palate,  $2\text{mm} \times 11\text{mm}$  Benefit mini-implants were inserted in the space between the lower left ca-

**TABLE 1  
CEPHALOMETRIC ANALYSIS**

	Norm	Pre-treatment	Post-Treatment
SNA	$82.0^\circ \pm 3.0^\circ$	$79.8^\circ$	$80.0^\circ$
SNB	$80.0^\circ \pm 3.0^\circ$	$85.6^\circ$	$80.0^\circ$
ANB	$2.0^\circ \pm 2.0^\circ$	$-5.8^\circ$	$-1.0^\circ$
Wits appraisal	$1.0\text{mm} \pm 2.0\text{mm}$	$-4.5\text{mm}$	$6.8\text{mm}$
Maxillomandibular plane angle	$23.5^\circ \pm 3.0^\circ$	$14.4^\circ$	$21.2^\circ$
U1-Maxillary plane	$112.5^\circ \pm 3.0^\circ$	$109.9^\circ$	$112.2^\circ$
L1-Mandibular plane	$90.0^\circ \pm 3.0^\circ$	$88.4^\circ$	$78.9^\circ$
U1-L1	$131.0^\circ \pm 3.0^\circ$	$147.4^\circ$	$147.7^\circ$
Overjet	$2.0\text{mm} \pm 2.0\text{mm}$	$-5.5\text{mm}$	$4.0\text{mm}$
Overbite	$2.0\text{mm} \pm 2.0\text{mm}$	$8.1\text{mm}$	$2.0\text{mm}$
Sagittal compensation	$0.0\text{mm} \pm 2.0\text{mm}$	$-3.0\text{mm}$	$2.0\text{mm}$

nine and first premolar and in the lower left first-molar site, and  $2\text{mm} \times 9\text{mm}$  Benefit mini-implants were inserted in the lower right first- and second-molar sites. Shorter miniscrews were used on the right side because of atrophic bone in that region.

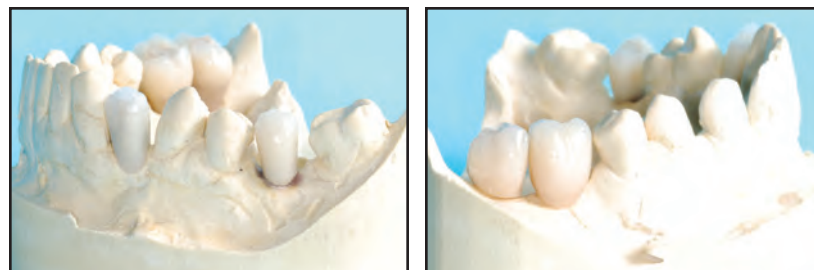
Alginate impressions were taken for a Mesialslider\* and for temporary crowns over the mandibular mini-implants (Fig. 2). Ten days later, the Propel\*\* system was used under local anesthesia to create microperforations in the maxillary first-premolar sites and thus accelerate space closure.

The Mesialslider and temporary crowns were then placed, along with full upper and lower fixed appliances (Fig. 3A). In addition, an occlusal splint supported only by the temporary crowns was delivered for full-time wear to help correct the anterior crossbite and prevent jiggling of the natural teeth (Fig. 3B).

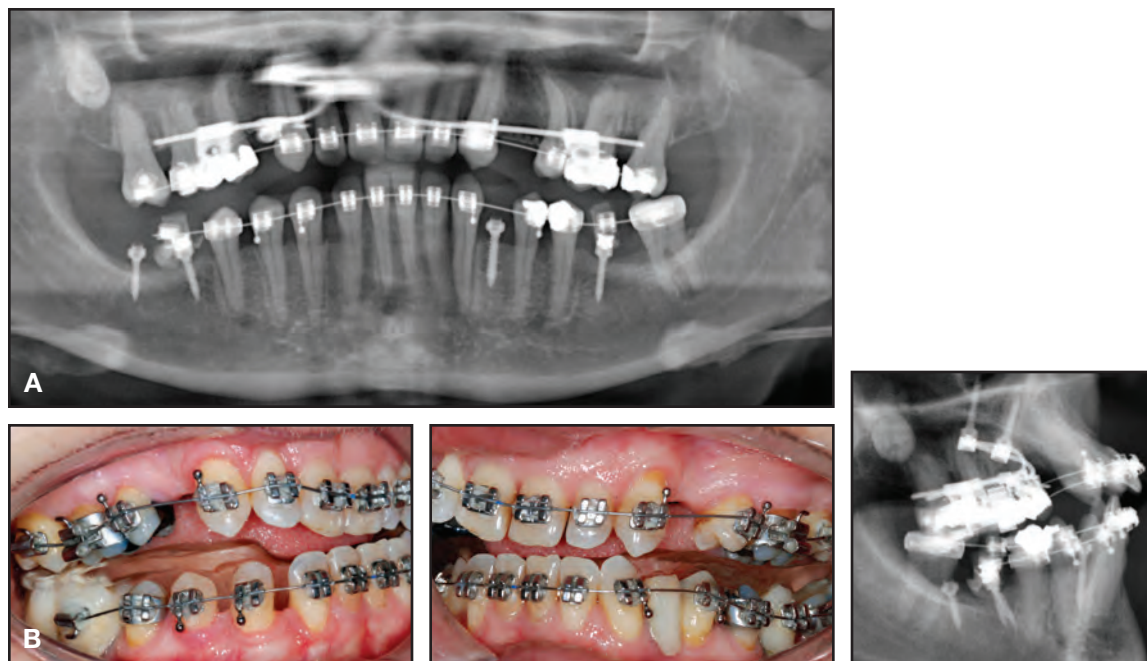
Archwires were changed at six-to-eight-week intervals, pro-

\*PSM Medical Solutions, Tuttlingen, Germany; www.psm.ms. Distributed in the U.S. by Mondeal North America, Inc., Indio, CA; www.mondeal-ortho.com.

\*\*Propel Orthodontics, Briarcliff Manor, NY; www.propelorthodontics.com.



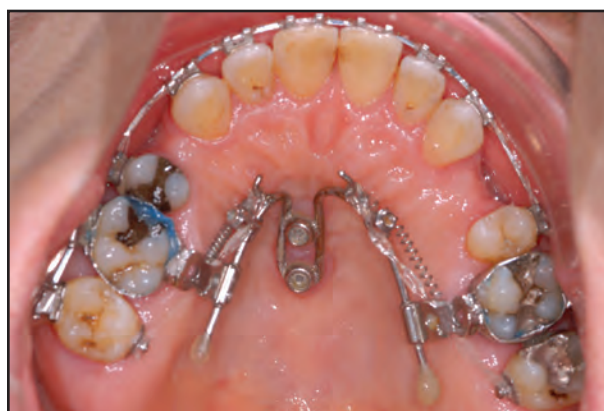**Fig. 2 Temporary crowns prepared for mini-implants in lower left and right quadrants.**



**Fig. 3 A.** Mesialslider and lower temporary crowns placed 10 days after insertion of palatal and mandibular mini-implants. **B.** Occlusal splint supported solely by temporary crowns inserted for disclusion during space closure and correction of anterior crossbite.

gressing from Supercable\*\*\* to .012" nickel titanium, .016" nickel titanium, .018" nickel titanium, .016" × .025" nickel titanium, .016" × .025" stainless steel, and .017" × .025" TMA.†

After eight months of treatment, the anterior crossbite had been corrected (Fig. 4). The occlusal splint and the mandibular temporary crowns were then removed, and the first rectangular archwire was inserted. While the lower left mini-implants were removed so that the spaces could be closed, the mini-implants on the lower right side were left in place to assist with anchorage during the mesialization of the lower left premolars and second molar. The Mesialslider supported the ante-



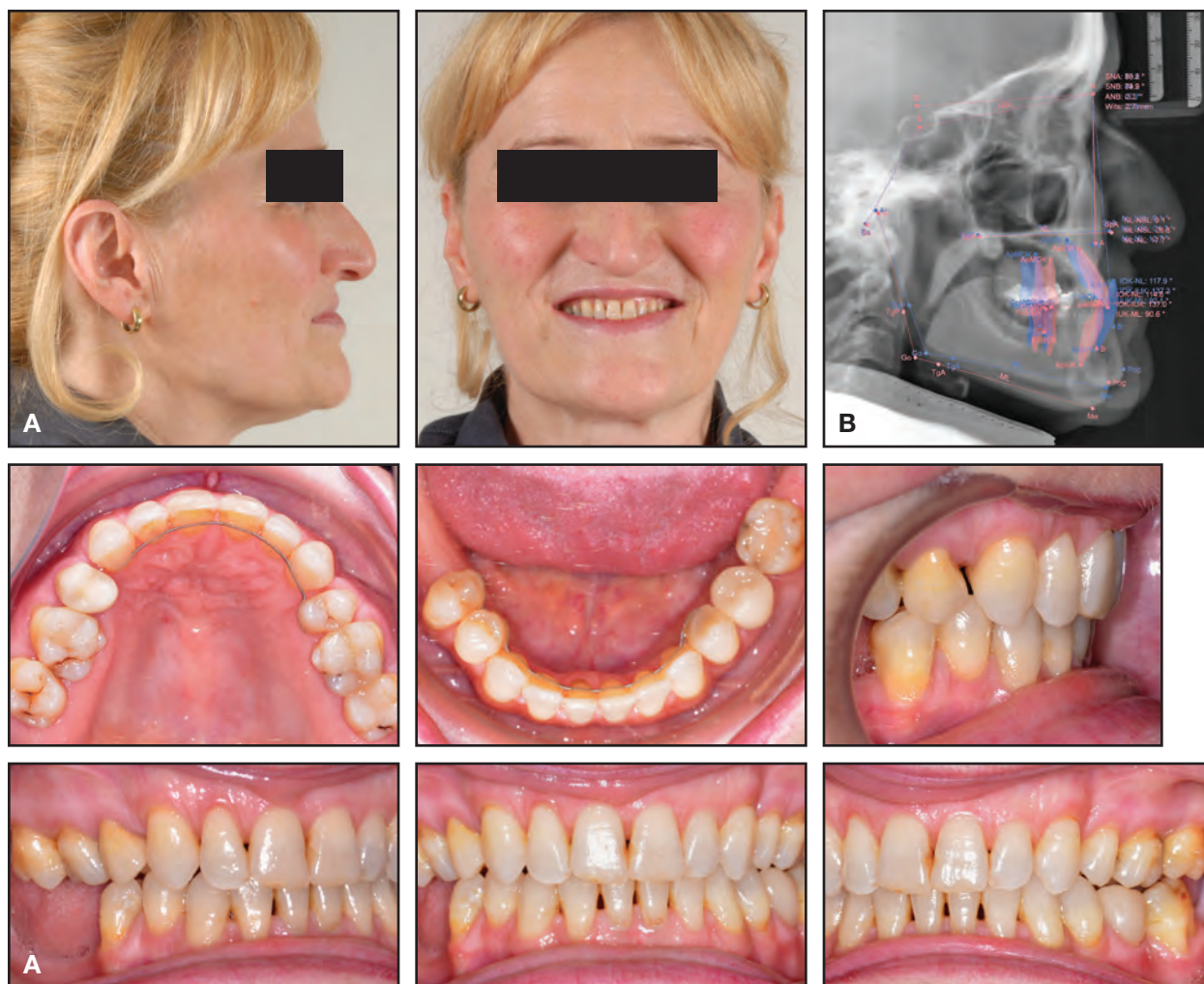
**Fig. 4** After eight months of Mesialslider activation.

rior-crossbite correction by means of protrusion with wire-driven mechanics. In this system of reverse anchorage loss, the friction between the molar brackets and archwire moved the archwire mesially, causing the premolars and canines to move mesially and the incisors to move forward.

During closure of the remaining maxillary spaces, the Mesialslider was left in the palate as anchorage, with the spring coils removed and interlock attachments inserted. An .017" × .025" TMA retraction wire was placed to establish proper overjet and overbite.

\*\*\*Trademark of Strite Industries Ltd., Cambridge, ON; [www.speedsystem.com](http://www.speedsystem.com).

†Registered trademark of Ormco Corporation, Orange, CA; [www.ormco.com](http://www.ormco.com).



**Fig. 5 A.** Patient after 36 months of orthodontic treatment and partial prosthetic restoration in lower arch. **B.** Superimposition of pre- and post-treatment cephalometric tracings.

Fixed-appliance treatment was completed in 36 months, and prosthetic restorations were scheduled soon after that.

### Treatment Results

Without surgery and with only dentoalveolar changes, the treatment results were satisfactory (Fig. 5). A Class I relationship with proper alignment was established; tooth positions were controlled while the maxillary

incisors were proclined, thus improving the incisor inclination, upper-lip prominence, and profile (Table 1). Skeletally, however, the mandible and chin were still slightly prognathic.

### Discussion

Skeletal Class III malocclusion is characterized by maxillary deficiency, mandibular prognathism, or both.<sup>6-10</sup> In a patient with mandibular prognathism, the best

solution often involves surgical maxillary advancement, mandibular setback, or a combination of the two, depending on the amount of skeletal discrepancy. Presurgical decompensation may require extraction of maxillary buccal teeth and retraction of the incisors. Maximum anchorage of the maxillary molars will be needed to achieve a significant increase in a negative overjet.

An alternative for Class III patients who are reluctant to un-

dergo surgery or who are satisfied with their facial appearance is to use dentoalveolar compensation—orthodontic protrusion of the upper anterior teeth and retrusion of the lower anterior teeth—without correcting the underlying skeletal deformity.<sup>11,12</sup> Although protrusion is relatively easy to achieve by aligning the anterior teeth during the leveling stage, it is more difficult to control the torque of anterior teeth during mesialization of the posterior teeth and space closure in patients with missing premolars. Conventional methods of torque control include Class III elastics, J-hook headgear, and archwire bends such as palatal root torque.

Class III patients with reduced lower facial height, deep overbite, and passive lip seal present a better prognosis because the treatment-induced backward rotation of the mandible will assist in camouflaging the anteroposterior discrepancy. Also helpful are palatally inclined maxillary incisors that can be moved labially and labially inclined mandibular incisors that can be moved lingually—even to overcorrected positions—to establish a normal overjet.<sup>7</sup> Our patient began with a significant skeletal discrepancy, but the presence of slightly retrusive maxillary incisors and a functional shift with a nearly end-to-end incisor relationship in CR made nonsurgical treatment a viable option.

Larger mini-implants, at least 2mm × 11mm, are preferred for the support of temporary crowns, but the 2mm × 9mm miniscrews that had to be used in

this case due to bone atrophy also remained stable throughout treatment. The mini-implant method shown here illustrates the faster tooth movement that can be achieved with the application of microperforation techniques. It is worth considering that mini-implants left in place over a period of months may stimulate the bone's metabolism, comparable to repeated corticotomy.<sup>13</sup>

Careful placement of the temporary crowns in relation to the natural teeth allowed the occlusal splint to disclude the dentition without jiggling movements. By grinding splint material away from the cusp areas of the natural teeth, we were able to simultaneously align the upper and lower arches and correct the anterior crossbite, which also helped reduce treatment time.

## Conclusion

Dentoalveolar compensation may be the treatment of choice for an adult Class III patient who does not want to undergo surgery. The clinician needs to weigh the risks and benefits before embarking on orthodontic therapy in any case where the results are uncertain. The mechanics described here, using a Mesialslider on Benefit mini-implants in the maxilla and an occlusal splint on temporary crowns and Benefit mini-implants in the mandibular arch, seemed to provide a stable dentoalveolar response within a short treatment time in this mature adult patient.

## REFERENCES

1. Kanomi, R.: Mini-implant for orthodontic anchorage, *J. Clin. Orthod.* 31:763-767, 1997.
2. Wilmes, B.: Fields of application of mini-implants, in *Mini-Implants in Orthodontics: Innovative Anchorage Concepts*, ed. B. Ludwig, S. Baumgaertel, and S.J. Bowman, Quintessence, Berlin, 2008, pp. 91-122.
3. Wilmes, B. and Drescher, D.: A mini-screw system with interchangeable abutments, *J. Clin. Orthod.* 42:574-580, 2008.
4. Wilmes, B. and Drescher, D.: Verankerung mit Miniimplantaten bei präprothetischer kieferorthopädischer Therapie, *Kieferorthop.* 20:203-208, 2006.
5. Wilmes, B.; Rademacher, C.; Olthoff, G.; and Drescher, D.: Parameters affecting primary stability of orthodontic mini-implants, *J. Orofac. Orthop.* 67:162-174, 2006.
6. Ngan, P.; Hagg, U.; Yiu, C.; Merwin, D.; and Wei, S.H.Y.: Soft tissue and dento-skeletal profile changes associated with maxillary expansion and protraction headgear treatment, *Am. J. Orthod.* 109:38-49, 1996.
7. Sanborn, R.T.: Differences between the facial skeletal patterns of Class III malocclusion and normal occlusion, *Angle Orthod.* 25:208-222, 1955.
8. Guyer, E.C.; Ellis, E. III; McNamara, J.A. Jr.; and Behrents, R.G.: Components of Class III malocclusion in juveniles and adolescents, *Angle Orthod.* 56:7-30, 1986.
9. Williams, S. and Andersen, C.E.: The morphology of the potential Class III pattern in the growing child, *Am. J. Orthod.* 89:302-311, 1986.
10. Mossey, P.A.: The heritability of malocclusion, Part 2: The influence of genetics in malocclusion, *Br. J. Orthod.* 26:195-203, 1989.
11. Ellis, E. III and McNamara, J.A. Jr.: Components of adult Class III malocclusion, *J. Oral Maxillofac. Surg.* 42:295-305, 1984.
12. Worms, F.W.; Isaacson, R.J.; and Speidel, T.M.: Surgical orthodontic treatment planning: Profile analysis and mandibular surgery, *Angle Orthod.* 46:1-25, 1976.
13. Long, H.; Pyakurel, U.; Wang, Y.; Liao, L.; Zhou, Y.; and Lai, W.: Interventions for accelerating orthodontic tooth movement, *Angle Orthod.* 83:164-171, 2013.