
Mini-implant-anchored Mesialslider for simultaneous mesialisation and intrusion of upper molars in an anterior open bite case: a three-year follow-up

Benedict Wilmes,* Vandana Katyal,† Jan Willmann,* Bruce Stocker* and Dieter Drescher*

Department of Orthodontics, University of Düsseldorf, Düsseldorf, Germany* and Australian Society of Orthodontists Foundation for Research and Education, Sydney, Australia†

Background: The present case report describes the orthodontic treatment and long-term follow-up of an adult female patient (27 years) who was diagnosed with a mild Class III malocclusion characterised by an anterior and lateral open bite and three periodontally-compromised first permanent molars.

Aim: The aim of treatment was to provide an acceptable aesthetic and functional occlusion while, at the same time, improving the periodontal prognosis.

Methods: The patient was treated with fixed orthodontic appliances utilising direct and indirect skeletal anchorage derived from two mini-screws placed in the palate and one mandibular buccal mini-screw.

Results: The objectives of good aesthetics, a functional occlusion, a healthy periodontium and a balanced profile were achieved. The total treatment time was 31 months, which comprised 13 months of maxillary fixed labial appliances and 25 months of mandibular fixed labial appliances. The three-year follow-up records showed stability of the Class III correction. (Aust Orthod J 2015; 31: 87–97)

Received for publication: December 2014

Accepted: April 2015

Benedict Wilmes: wilmes@med.uni-duesseldorf.de; Vandana Katyal: vandykatyal@gmail.com;

Jan Willmann: Jan.Willmann@med.uni-duesseldorf.de; Bruce Stocker: Bruce.Stocker@med.uni-duesseldorf.de;

Dieter Drescher: d.drescher@uni-duesseldorf.de

Introduction

The tooth most commonly lost to dental caries or periodontal disease is the first permanent molar.¹ Although a partial or fixed prosthesis can be used to replace missing teeth, orthodontic space closure by substitution with the second and third permanent molars is also a viable option.²⁻⁵ Treatment is difficult when protraction of the second and third molars is required without retraction of the anterior teeth. In addition, treatment is more complicated if the patient has an anterior open bite and requires maxillary posterior intrusion.

Recently, titanium mini-implants have become popular for providing absolute anchorage during tooth movement as they are simpler, cheaper and more convenient than endosseous implants that have previously been used.^{2,4,6-10} The mini-implants have pushed the envelope for tooth movement with the potential benefit of avoiding bimaxillary surgery in selected cases.¹¹ The commonly reported site for mini-implant insertion is the buccal dento-alveolar region, which may place the miniscrew in the path of moving teeth. Hence, particularly in the maxilla, the anterior palate is an advantageous insertion site since all teeth can be moved without interference from the mini-implants.¹²

Further advantages of the anterior palate are good bone quality, a thin attached mucosa, minimal risk of a tooth injury and a very high success rate.^{13,14} However, in the mandible, the buccal dento-alveolus remains the site of choice for mini-implant insertion.

The present case report describes the orthodontic management of an adult female patient (aged 27 years) who presented with an anterior and lateral open bite. Treatment required a combination of molar protraction and intrusion. The case also illustrates the mechanics of direct anchorage utilising two palatally-inserted mini-implants in the maxilla and indirect anchorage utilising one buccally-inserted mini-implant in the mandible.

The result of the orthodontic treatment, retention phase and follow-up care showed that good aesthetics, a functional occlusion and stability were achieved without complications related to mini-implant use.

Diagnosis and aetiology

An adult female, aged 27 years, sought orthodontic treatment because of an anterior open bite and posterior spacing due to recent extractions of periodontally-involved lower right and upper left permanent first molars. The extractions were performed one month prior to the initial orthodontic consultation and three months prior to the commencement of orthodontic treatment.

The patient presented with a straight profile and an increased lower anterior facial height. There was a mild skeletal asymmetry as the chin was to the left of the facial midline. On posed smiling, 75% of the length of the upper central incisors was displayed and the smile arc was non-consonant with the lower lip. Intra-orally, anterior (3.5 mm) and bilateral open bites were present. A Class III incisor and canine relationship was evident and accumulated anterior spacing of 10 mm was measured in the lower arch and 9 mm in the upper arch. Supra-eruption of the upper second molars had occurred, along with advanced periodontal bone loss around the upper right first permanent molar, which compromised the long-term prognosis of this tooth. The maxillary dental midline was coincident with the facial midline but the mandibular dental and skeletal midlines had deviated 2 mm to the left. The pretreatment photographs and dental cast are shown in Figure 1 and Figure 2, respectively.

The initial panoramic radiograph revealed the advanced bone loss around all permanent first molars except on the lower left side where minimal bone loss had occurred. The upper left third molar was present but unerupted due to a distoangular impaction (Figure 3). The initial cephalometric analysis showed a moderate Class III sagittal discrepancy (ANB angle 1°, WITS -4.5 mm) with a hyperdivergent vertical pattern and an increased gonial angle (Figure 4, Table I).

Table I. Changes in cephalometric variables before and after treatment.

Cephalometric variables	Before treatment (T ₁)	At debonding (T ₂)	Change (T ₂ -T ₁)
SNA (°)	81.6	81.0	-0.6
SNB (°)	80.5	80.8	0.3
ANB (°)	1.1	0.2	-0.9
WITS (mm)	-4.5	-4.9	0.4
SN-PP (°)	2.8	2.9	0.1
SN-MP (°)	32.0	30.1	-0.9
PP-MP (°)	29.2	27.2	-2.0
ArGoMe (°)	121.0	121.0	0
UI-PP (°)	110.3	111.6	1.3
UI-MP (°)	97.7	98.1	0.4
U-LI (°)	122.4	123.1	0.7
OJ (mm)	1.3	3.2	1.9
OB (mm)	-4.0	1.5	5.5

SNA, Angle Sella-Nasion-A point; SNB, Angle Sella-Nasion-B point; ANB, Difference of SNB and SNA; WITS, Linear difference between B point and A point on functional occlusal plane; SN-PP, Angle Sella-Nasion line to Palatal plane; SN-MP, Angle Sella-Nasion line to Mandibular plane; PP-MP, Angle between Palatal and Mandibular planes; ArGoMe, Angle between Articulare-Gonion-Menton; UI-PP, Angle between Upper incisor long axis and Palatal plane; LI-MP, Angle between lower incisor long axis and Mandibular plane; U-LI, Angle between long axes of Upper and Lower incisor; OJ, Overjet; OB, Overbite.

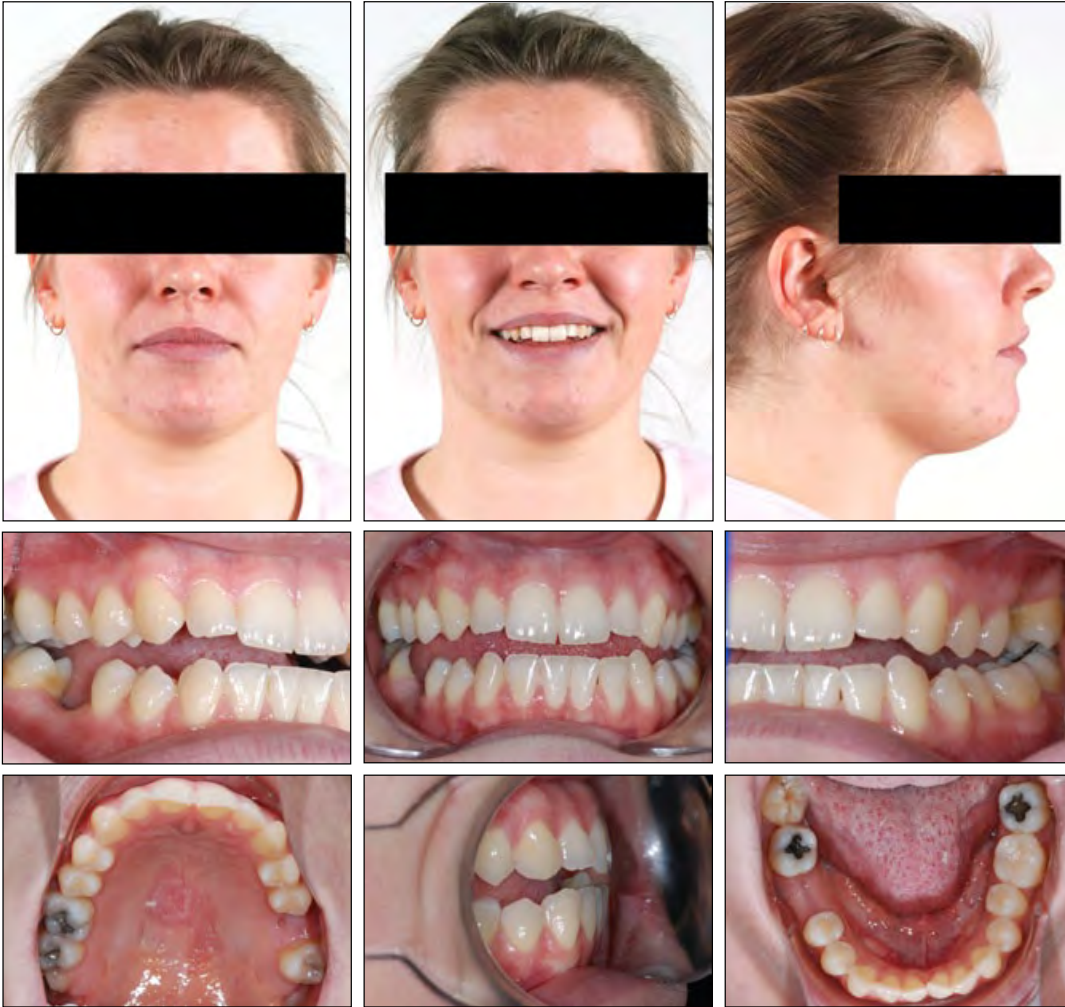

Figure 1. Pretreatment facial and intra-oral photographs.

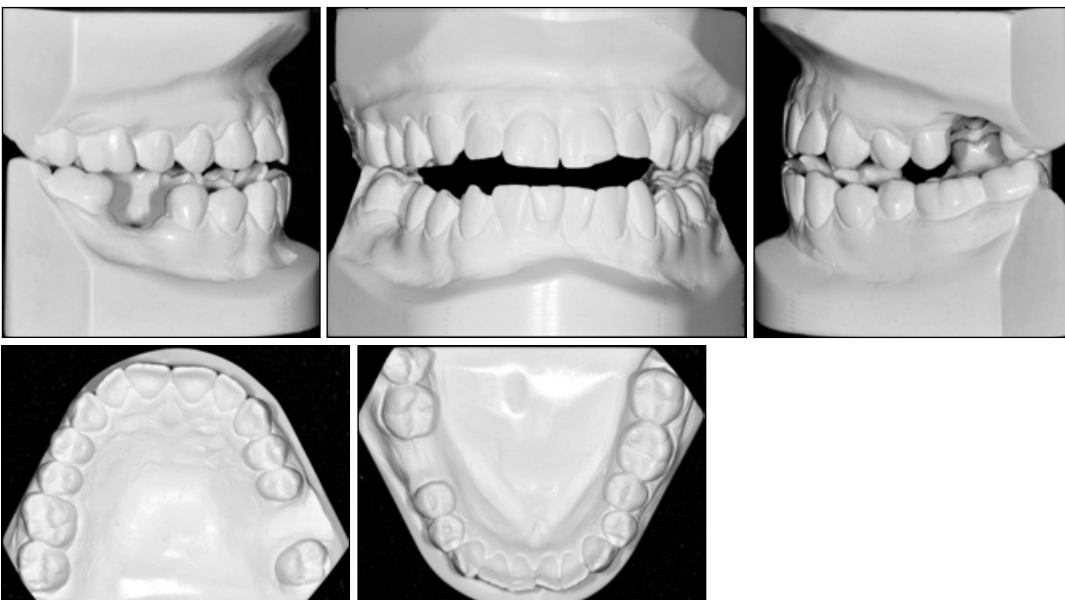


Figure 2. Photographs of pretreatment dental casts.

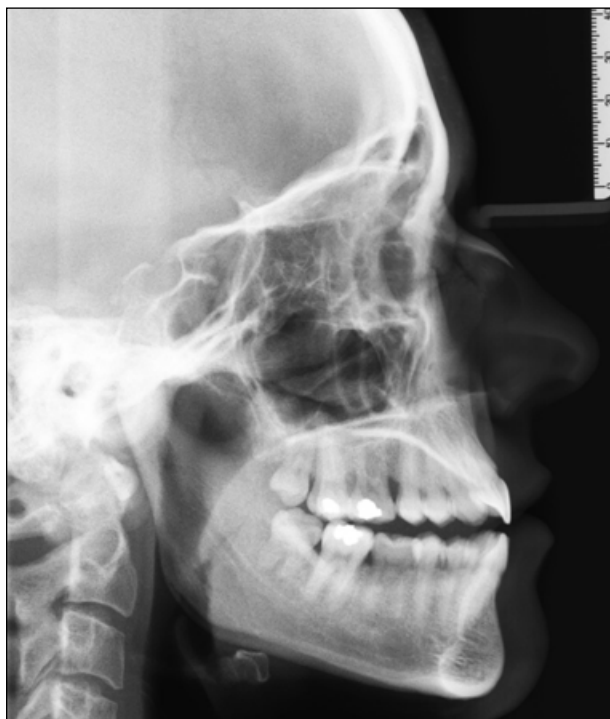

Figure 3. Pretreatment panoramic radiograph.

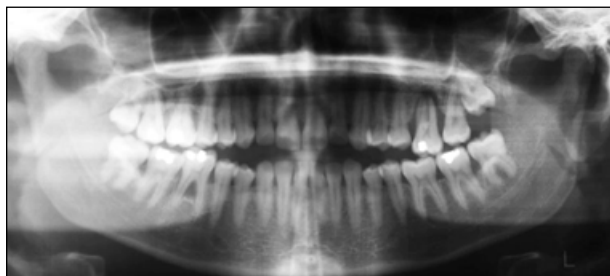

Figure 4. Pretreatment lateral cephalogram.

The functional assessment of the occlusion did not show a discrepancy between centric occlusion and centric relation. There were no signs or symptoms of temporomandibular dysfunction. The advanced periodontitis and bone loss was localised primarily to the first molars in three quadrants but there were no additional medical or dental concerns.

Treatment objectives

After informed consent was granted, a decision was made in consultation with the patient to extract the periodontally-involved upper right permanent first molar to balance the previously extracted first molars. It was planned to maintain the antero-posterior position of the upper and lower incisors, since there were no significant facial profile concerns. The treatment objectives were to close the posterior spaces

by protraction of second and third molars and closure of the anterior open bite primarily by intrusion of upper posterior teeth but with some anterior extrusion to improve maxillary incisor display on smiling.

Treatment progress

It was considered that the treatment objective of molar mesialisation would place a high demand on anterior anchorage. Additionally, the required intrusion of the maxillary second molars was expected to be challenging with conventional mechanics. A Mesialslider (1.1 mm stainless steel wire) connected to two median palatal mini-implants (2 × 11 mm anterior and 2 × 9 mm posterior, Benefit system), described and reported previously by Wilmes et al.,^{6,7,10} was planned for the upper arch as a source of direct anchorage, and a single buccally-placed mini-implant (1.6 × 8 mm, Dual Top system) on the right side was planned for the lower arch as a source of indirect anchorage.

Under local anaesthesia, treatment commenced with the insertion of the two palatal mini-implants distal to the third rugae. After mini-implant insertion, bands were fitted to the upper second molars and an impression was taken for laboratory bending of the Mesialslider. The two arms of the Mesialslider were angulated apically to the occlusal plane to facilitate intrusion during the anterior movement of the upper second molars (Figure 5).

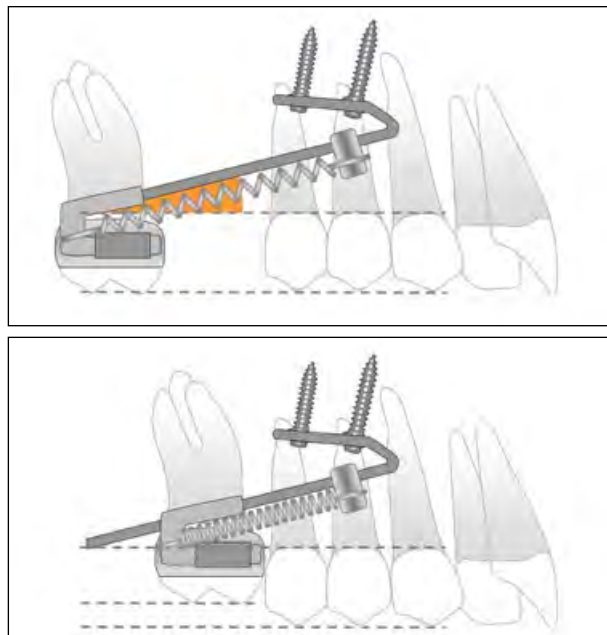


Figure 5. Principle of simultaneous intrusion and mesialisation of upper second molars.

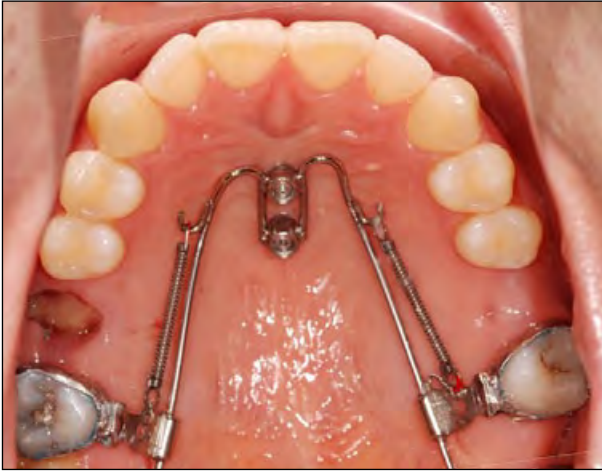

Figure 6. Occlusal view of the Mesialslider attached to two palatal mini-implants at the start of maxillary molar mesialisation.

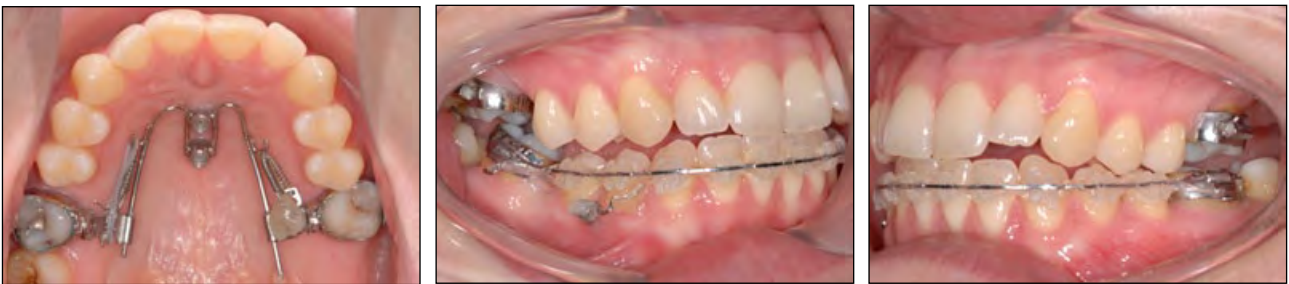

Figure 7. Intra-oral photographs 12 months into treatment highlighting the excellent intrusion achieved for maxillary second molars during mesialisation.

The Mesialslider attached to upper molar bands was subsequently cemented (Figure 6) along with the lower second molar bands. No brackets were bonded to the upper arch at this time. The mesialisation of the maxillary molars commenced using bilateral Nickel-Titanium closing coil spring (200 g). The lower right second molar and premolar were connected with a sectional archwire (0.016 × 0.022 inch, stainless steel). Six months into treatment, a mandibular right buccal mini-implant was inserted between the lower right first and second premolars and a full fixed labial orthodontic appliance was bonded. The mini-implant was connected to the lower right first premolar with a wire (0.017 × 0.025 inch, stainless steel) and composite resin. The mesialisation of the lower right second molar was commenced using elastic power chain.

Following one year of treatment, the intrusion and mesialisation of the upper left second molar had been achieved and the Mesialslider was discontinued on the left side and re-activated to continue the unilateral intrusion and mesialisation of the upper right second

molar (Figure 7). An elastic chain was added in addition to the existing Ni-Ti coil spring to increase the mesialising forces on the upper right second molar. Additionally, excellent intrusion of the maxillary left and right second molars was achieved, which produced a 2–3 mm occlusal clearance from the mandibular molars. Following maxillary molar intrusion, upper labial fixed appliances (0.018 × 0.025 inch pre-adjusted appliance) were attached, approximately 18 months after the commencement of treatment. As the second molars were directly anchored to the two palatal mini-implants, the initial aligning wires intruded the premolars, which resulted in a favourable change in the occlusal plane. This intrusion effect decreased anteriorly. Twenty-two months after commencement, upper molar mesialisation and intrusion, along with space closure, had been completed and the Mesialslider was removed (Figure 8). One palatal mini-implant was left in situ and subsequently utilised to achieve transverse arch coordination (Figure 9). At 29 months, all spaces were closed and a Class I occlusion, with an ideal overbite, overjet and coincident midlines were

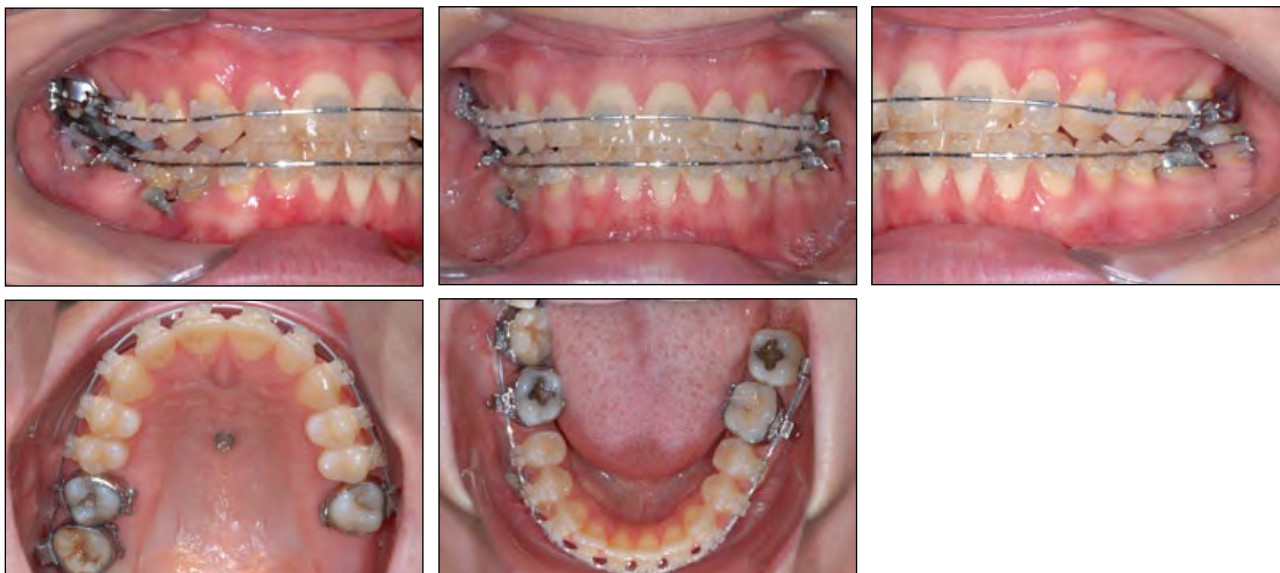


Figure 8. Mid-treatment intra-oral photographs (after completion of maxillary space closure and removal of Mesialslider and one palatal mini-screw).

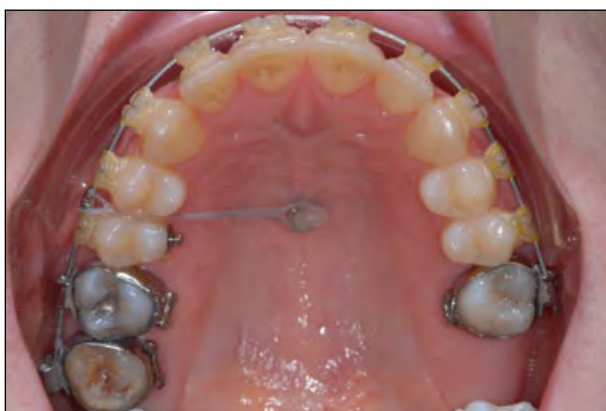

Figure 9. Utilisation of the remaining palatal mini-screw as a source of direct anchorage to achieve transverse arch coordination.

achieved. After finishing and detailing, the appliances and mini-implants were removed, which saw active treatment conclude at 31 months. Passive anterior fixed lingual retainers were bonded in the maxillary and mandibular arches.

Treatment results

All of the planned treatment objectives were met. The mandibular and maxillary arches were aligned with an established Class I canine relationship, normal overbite and overjet and coincident dental midlines. The debonding records are shown in Figure 10 and corresponding dental models in Figure 11.

The final panoramic radiograph (Figure 12) shows bodily mesialisation of the three second molars into

the first molar spaces and good alveolar bone levels. During the extraction of the upper right first molar, the oral and maxillofacial surgeon also extracted the distoangularly impacted upper left third molar. This was unfortunate as it might have been possible to erupt and mesialise this tooth into the arch. The lateral cephalogram (Figure 13, Table I) indicates good skeletal sagittal and vertical balance with maintained incisor angulations and maxillary posterior dental intrusion. The mandibular hyperdivergence has reduced, which suggests that an autorotation of the mandible in an upward and forward direction has occurred. Retention was completed three years after appliance removal and the retention records show good stability of the achieved changes (Figure 14). No relapse of the anterior open bite was noted. The bonded fixed lingual retainers caused no complications.

The pre- and post-treatment lateral cephalograms were superimposed (Figure 15) on Sella-Nasion line at Sella (Table I) and confirm the preservation of anterior anchorage, intrusion of the maxillary second molars and mild closure of the maxilla-mandibular hyperdivergence due to the occlusal plane changes. There were no other significant skeletal, dental or soft tissue changes seen.

Discussion

Besides orthodontic space closure by molar mesialisation, spaces resulting from the loss of first permanent molars could also be managed by

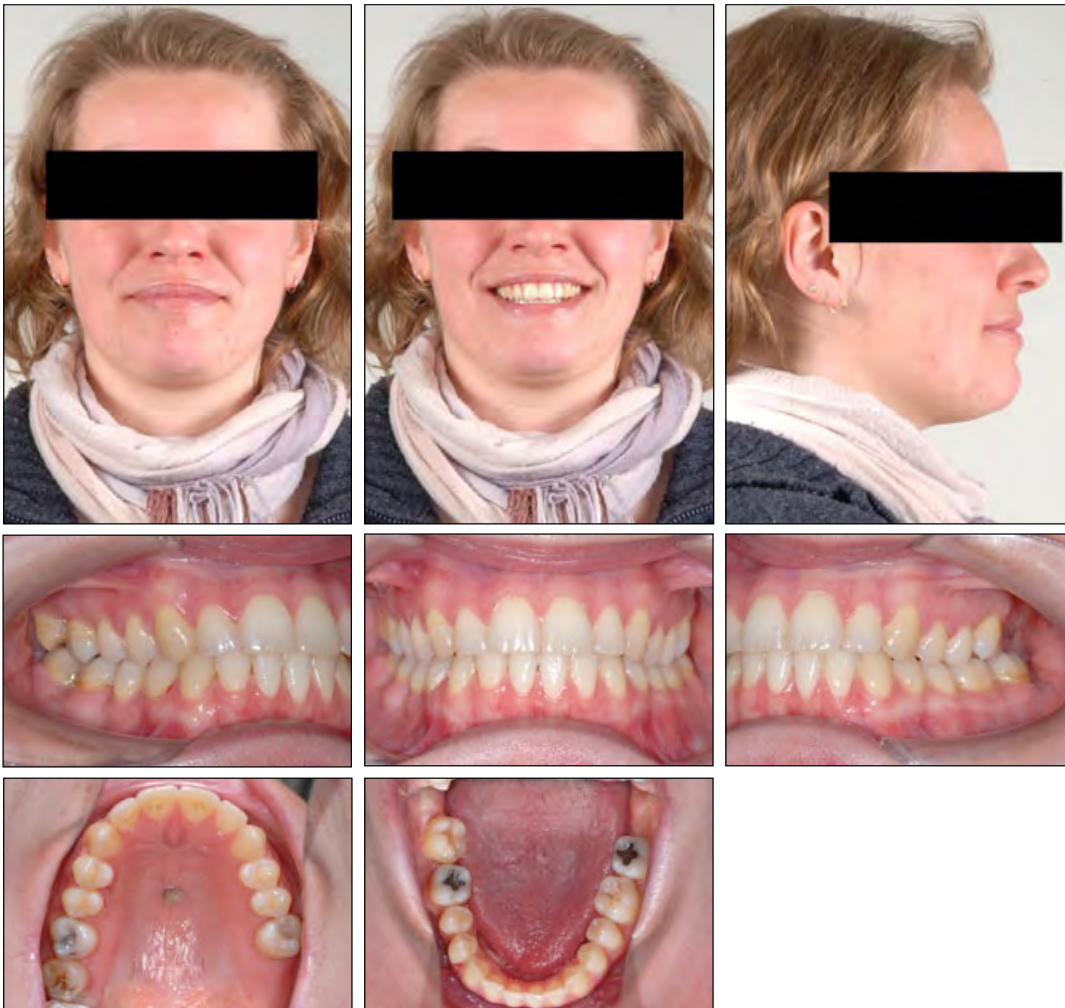

Figure 10. Facial and intra-oral photographs immediately after debonding of all appliances. The palatal mini-implant seen here was removed soon after this time-point.

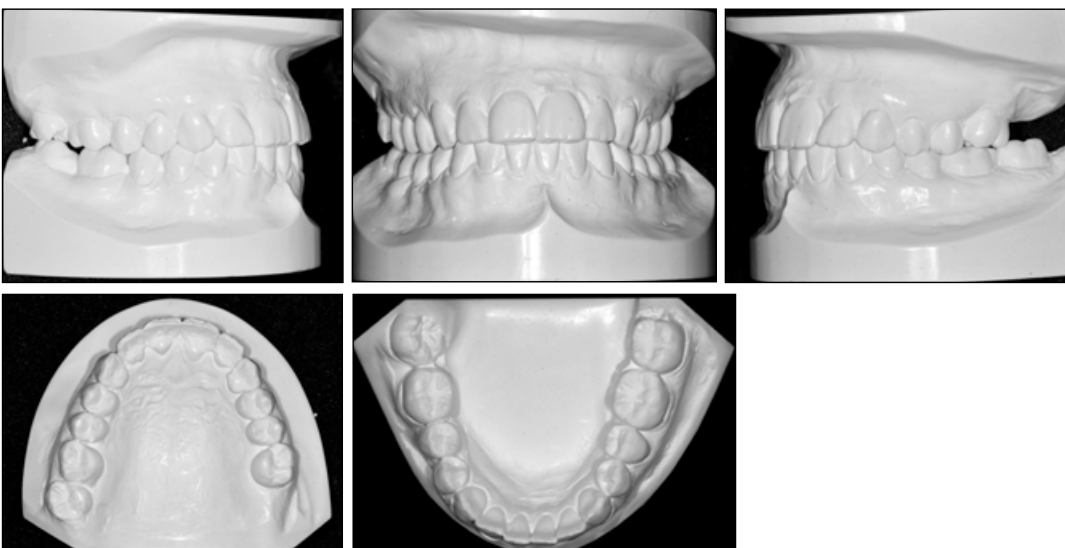


Figure 11. Photographs of dental casts immediately after debonding of all appliances.

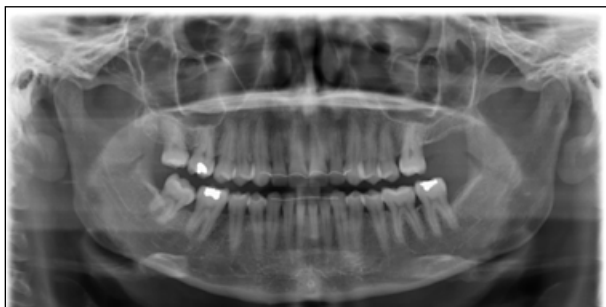

Figure 12. Panoramic radiograph immediately after debonding and completion of active orthodontic treatment.

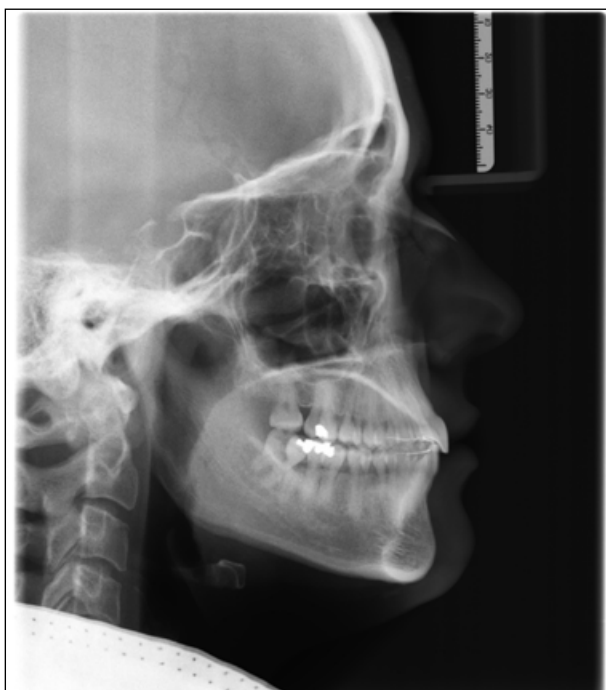

Figure 13. Lateral cephalogram immediately after debonding and completion of active orthodontic treatment.

a removable or fixed prosthesis, dental implants or autotransplantation of the third molars. These prosthetic options reduce treatment time but require surgery (dental implants, autotransplantation) and significant tooth preparation (fixed prosthesis). Variable long-term survival rates and complications of the alternative prosthetic and surgical options have been reported.^{15,16} Additionally, to improve facial vertical proportions and chin asymmetry, orthognathic jaw surgery may also be an option.

The presented patient avoided orthognathic surgery and chose orthodontic space closure by molar mesialisation. Since this was a challenging malocclusion to correct without a surgical option, mini-implants as temporary anchorage devices were considered to facilitate the sagittal, transverse and vertical orthodontic corrections.

There has been a recent increase in published case reports and clinical studies that highlight the mesialisation of second and third molars into the spaces created by missing first molars.^{2-4,6,17-19} However, the present patient differed from previously reported cases.

Firstly, the requirement to reinforce anterior and vertical anchorage was high. Secondly, space closure in the mandibular arch was performed unilaterally and required anchorage reinforcement. Finally, the maxillary and mandibular fixed appliances were not bonded until well into treatment (18 months and 6 months, respectively). Hence, although treatment time was 31 months, the time in fixed appliances was

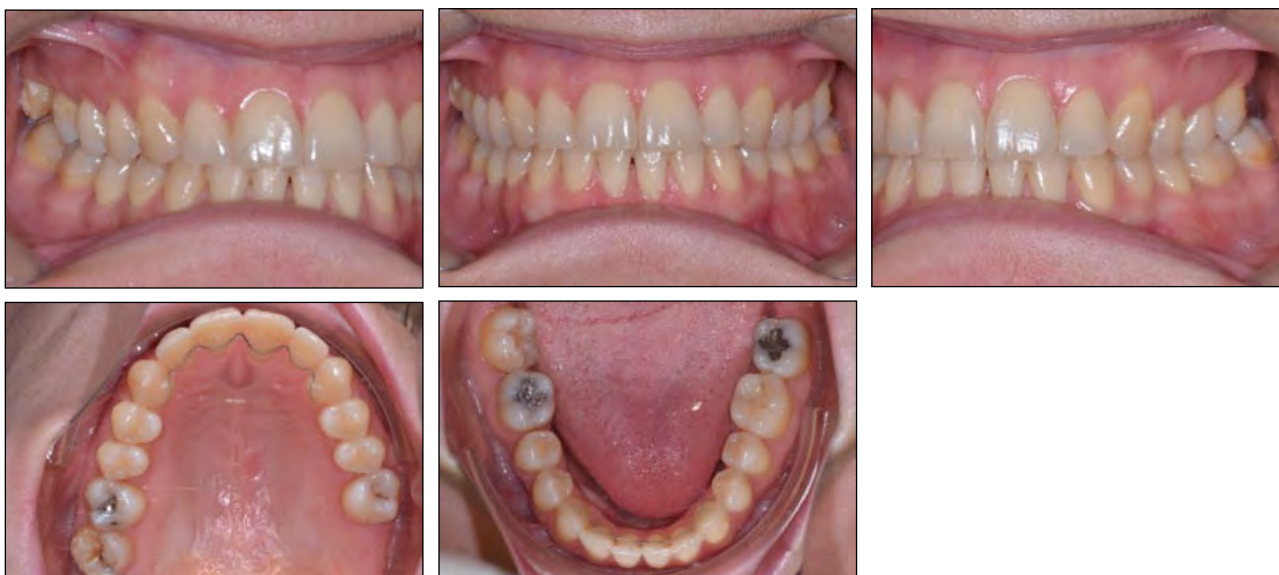

Figure 14. Intra-oral photographs at three years in retention.

13 months for the maxillary arch and 25 months for the lower arch.

The cephalometrically-measured treatment effects revealed that there was minimal change in the upper and lower incisor angulations, which suggested preservation of anterior anchorage during molar mesialisation. During mesialisation, bodily movement is preferred rather than tipping of the molar crowns so that periodontal complications are avoided. Although second molar positions indicate that bodily mesialisation was achieved, the upper right and lower right third molars show slight mesial tipping. This may have been corrected by re-bracketing the tipped molars for angulation control, the use of uprighting springs and/or anti-tipping archwire bends. Additionally, during mesialisation, the moment of force on the maxillary molars tended to rotate the teeth mesio-palatally around the palatal root and rotate the lower molars mesio-lingually. The upper right second molar rotated in the present case. Previous reports have recommended the use of rigid lingual bars⁴ or a buccally and lingually directed force on the molar³ to control molar rotation and tipping during mesial movement. However, this adverse effect was easily corrected with compensating anti-rotation archwire bends in the detailing phase of the current case. At the time of debonding, there were no significant rotations of the second and third molars.

Research using a finite element analysis has shown that the direct application of force from a mini-implant to a posterior molar requiring mesialisation (direct anchorage) produces lower strains on anchor teeth in comparison with indirect anchorage, particularly in the mandibular arch.¹⁷ Although the present patient was managed with a mandibular mini-implant as indirect anchorage, no significant anterior anchorage loss was noted.

Although all spaces were closed at the end of treatment, a small space of less than 1 mm reopened between lower right second molar and premolar. Stepovich²⁰ highlighted the difficulties in maintaining space closure after molar mesialisation in the mandibular arch. Nagaraj et al.³ recommended the use of a bonded sectional fixed wire retainer from premolar to molar to prevent space reopening. It was considered wise to provide the present patient with an additional removable lower Hawley retainer since there was a history of good compliance. Unfortunately, the patient failed to wear the mandibular retainer as instructed

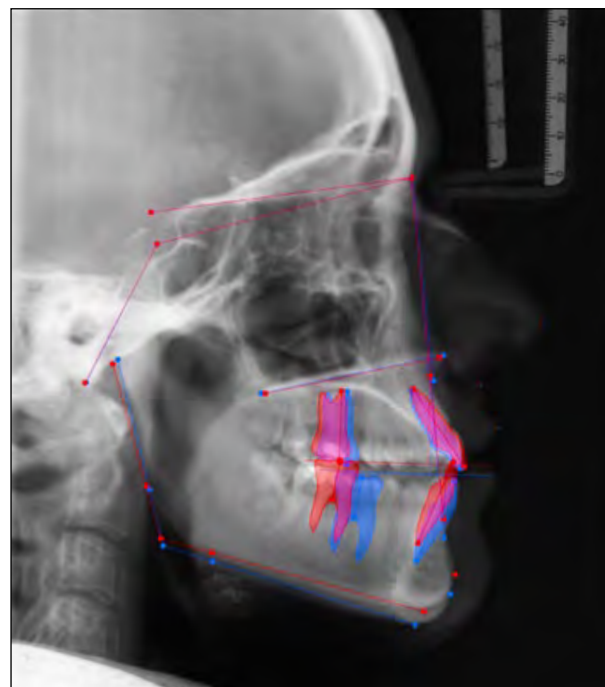


Figure 15. Superimposition of initial and treatment finish lateral cephalograms on cranial base (Sella-Nasion line on Sella point).

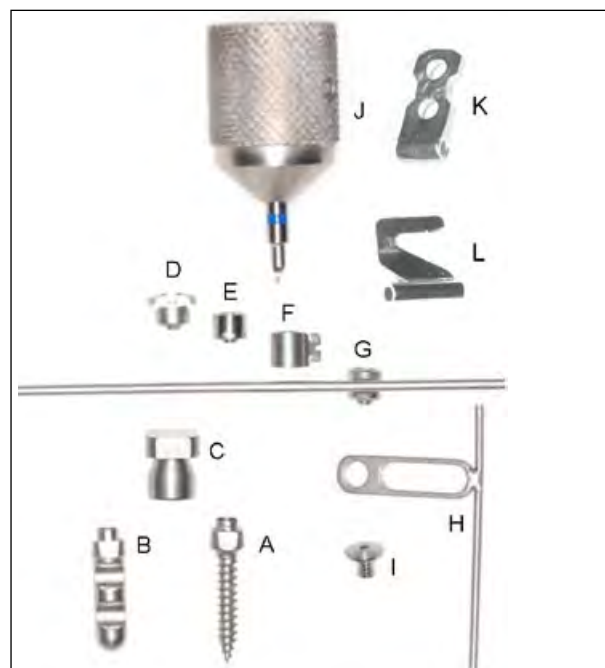


Figure 16. The Benefit Mini-Implant system and its constituent parts.

but the re-opened space has not been periodontally unfavourable because of the maintenance of good oral hygiene.

The challenging characteristics of the present case were the open bite (anterior and lateral), the increase in lower facial height and the supra-eruption of the

maxillary posterior teeth. When posterior teeth are mesialised with skeletal anchorage systems, accompanying extrusion can worsen the open bite.²¹ To prevent this occurrence, the Mesialslider guiding wires were bent and orientated in an apical direction prior to placement into the maxillary second molar bands. This achieved the desired maxillary posterior molar intrusion. Wilmes et al.^{6,7} have suggested that the Mesialslider can also be bent at chair-side. This negates the need for a dental laboratory and potentially saves the orthodontist in time and costs. The Mesialslider has also been proposed to assist mesialisation in cases presenting with missing anterior and posterior teeth. Hence, the appliance has a wide variety of applications for dentoalveolar sagittal movements. Figure 16 shows an image of the 'Benefit' system and its constituent parts for individual needs according to differing anchorage requirements. Although the present case required part K to be soldered to the maxillary molar bands as shown in Figure 16, contemporary fabrication suggests that part L can be inserted directly into a standard molar band sheath at chair-side, which avoids a laboratory soldering procedure.

It has been reported that maxillary molar intrusion is often followed by mandibular molar extrusion,²² which was observed in the present case. It might have been preferable to control mandibular molar extrusion to increase the counter-clockwise rotation of the occlusal plane. However, the final overbite and smile aesthetics showed acceptable improvement and stability three years after treatment.

All three second molars were mesialised into alveolar ridges that had been affected by previous periodontal bone loss. Animal²³ and human experiments²⁴ have shown that when a tooth is mesialised into a reduced bony ridge, the periodontal support of the newly moved tooth shows minimal breakdown. In addition, there may be a positive change in the width of the alveolar ridge.²⁴ This was evident in the presented case. One important and related factor is the excellent oral hygiene maintained by the patient throughout treatment.

The total treatment time was 31 months (2 years and 7 months), which was well within the reported average of 2–4 years for cases requiring molar mesialisation.²⁵ An important aspect was that active mesialisation of molars commenced soon after the extraction of the first molars. Furthermore, the total time in maxillary

labial fixed appliances was reduced to 13 months and for the mandibular fixed labial appliance to 25 months. This had the added benefit of maintaining maximal aesthetics during treatment and reducing the risks of enamel decalcification and root resorption. The shorter time in labial fixed appliances, especially in the maxillary arch, was made possible by the use of the Mesialslider initially to correct sagittal and vertical molar position. Once the molars were in their desired position, labial fixed appliances were used to level, finish and detail the case.

Relapse rates of 25–30% have been reported as a result of non-surgical correction of anterior open bites.²⁷ Most of the relapse occurs in the initial 12 months of retention. Fortunately, the present patient did not experience significant relapse of the overbite or of the final occlusion. This may have been related to the simultaneous intrusion and mesialisation movement of the second molars.

There were no significant complications seen or reported during and following orthodontic treatment. The patient was highly motivated and the periodontal status was maintained. The only unfortunate complication was the removal of the upper left third molar, which was not a part of the orthodontic plan. The loss of the upper third molar may promote the supra-eruption of an opposing molar. However, the good interdigitisation of the left side posterior teeth will likely maintain the position of the partially unopposed lower left third molar.

Conclusion

Bilateral maxillary orthodontic traction and simultaneous intrusion of the upper second molars into maxillary first molar spaces was made possible by mini-implant assisted mechanics. The retraction of anterior teeth was avoided in a complicated case that presented with anterior and lateral open bites. A total treatment time of 31 months was well within reported literature averages for molar mesialisation. The desired objectives of smile and facial aesthetics, a solid functional occlusion and stability were achieved without complications.

Corresponding author

Professor Benedict Wilmes
Department of Orthodontics

University of Düsseldorf
 Moorenstr. 5
 40225 Düsseldorf
 Germany
 Email: wilmes@med.uni-duesseldorf.de

References

1. Moyers RE. Handbook of Orthodontics. 2nd edn. Chicago, Illinois: Year Book Medical Publishers, Inc., 1966.
2. Baik UB, Chun YS, Jung MH, Sugawara J. Protraction of mandibular second and third molars into missing first molar spaces for a patient with an anterior open bite and anterior spacing. *Am J Orthod Dentofacial Orthop* 2012;141:783-95.
3. Nagaraj K, Upadhyay M, Yadav S. Titanium screw anchorage for protraction of mandibular second molars into first molar extraction sites. *Am J Orthod Dentofacial Orthop* 2008;134:583-91.
4. Kyung SH, Choi JH, Park YC. Miniscrew anchorage used to protract lower second molars into first molar extraction sites. *J Clin Orthod* 2003;37:575-9.
5. Roberts WE, Nelson CL, Goodacre CJ. Rigid implant anchorage to close a mandibular first molar extraction site. *J Clin Orthod* 1994;28:693-704.
6. Wilmes B, Nienkemper M, Nanda R, Lübberink G, Drescher D. Palatally anchored maxillary molar mesialization using the mesialslider. *J Clin Orthod* 2013;47:172-9.
7. Wilmes B, Drescher D. A miniscrew system with interchangeable abutments. *J Clin Orthod* 2008;42:574-80.
8. Wilmes B. Fields of application of mini-implants. In: Ludwig B, Baumgaertel S, Bowman SJ. *Mini-Implants in Orthodontics: Innovative Anchorage Concepts*. Berlin, New York: Quintessence Publishing Co Ltd, 2008;91-122.
9. Deguchi T, Takano-Yamamoto T, Kanomi R, Hartsfield JK Jr, Roberts WE, Garetto LP. The use of small titanium screws for orthodontic anchorage. *J Dent Res* 2003;82:377-81.
10. Wilmes B, Drescher D, Nienkemper M. A miniplate system for improved stability of skeletal anchorage. *J Clin Orthod* 2009;43:494-501.
11. Graber T, Vanarsdall R, Vig KWL. The decision-making process in orthodontics. In: *Orthodontics: current principles and techniques*. 5th edn. Philadelphia: Elsevier, 2012;3-58.
12. Ludwig B, Glasl B, Bowman SJ, Wilmes B, Kinzinger GS, Lisson JA. Anatomical guidelines for miniscrew insertion: palatal sites. *J Clin Orthod* 2011;45:433-41.
13. Lim HJ, Choi YJ, Evans CA, Hwang HS. Predictors of initial stability of orthodontic miniscrew implants. *Eur J Orthod* 2011;33:528-32.
14. Kim YH, Yang SM, Kim S, Lee JY, Kim KE, Gianelly AA et al. Midpalatal miniscrews for orthodontic anchorage: factors affecting clinical success. *Am J Orthod Dentofacial Orthop* 2010;137:66-72.
15. Pjetursson BE, Brägger U, Lang NP, Zwahlen M. Comparison of survival and complication rates of tooth-supported fixed dental prostheses (FDPs) and implant-supported FDPs and single crowns (SCs). *Clin Oral Implants Res* 2007;18:97-113.
16. Josefsson E, Brattström V, Tegsjö U, Valerius-Olsson H. Treatment of lower second premolar agenesis by autotransplantation: four-year evaluation of eighty patients. *Acta Odontol Scand* 1999;57:111-5.
17. Holberg C, Winterhalder P, Holberg N, Wichelhaus A, Rudzki-Janson I. Indirect miniscrew anchorage: biomechanical loading of the dental anchorage during mandibular molar protraction – an FEM analysis. *J Orofac Orthop* 2014;75:16-24.
18. Uribe F, Janakiraman N, Fattal AN, Schincaglia GP, Nanda R. Corticotomy-assisted molar protraction with the aid of temporary anchorage device. *Angle Orthod* 2013;83:1083-92.
19. Jacobs C, Jacobs-Müller C, Luley C, Erbe C, Wehrbein H. Orthodontic space closure after first molar extraction without skeletal anchorage. *J Orofac Orthop* 2011;72:51-60.
20. Stepovich ML. A clinical study on closing edentulous spaces in the mandible. *Angle Orthod* 1979;49:227-33.
21. Jung MH, Kim TW. Biomechanical considerations in treatment with miniscrew anchorage. Part 1: the sagittal plane. *J Clin Orthod* 2008;42:79-83.
22. Sugawara J, Baik UB, Umemori M, Takahashi I, Nagasaka H, Kawamura H et al. Treatment and posttreatment dentoalveolar changes following intrusion of mandibular molars with application of a skeletal anchorage system (SAS) for open bite correction. *Int J Adult Orthodon Orthognath Surg* 2002;17:243-53.
23. Lindskog-Stokland B, Wennström JL, Nyman S, Thilander B. Orthodontic tooth movement into edentulous areas with reduced bone height. An experimental study in the dog. *Eur J Orthod* 1993;15:89-96.
24. Lindskog-Stokland B, Hansen K, Ekstubb A, Wennström JL. Orthodontic tooth movement into edentulous ridge areas – a case series. *Eur J Orthod* 2013;35:277-85.
25. Hom BM, Turley PK. The effects of space closure of the mandibular first molar area in adults. *Am J Orthod* 1984;85:457-69.
26. Li W, Chen F, Zhang F, Ding W, Ye Q, Shi J et al. Volumetric measurement of root resorption following molar mini-screw implant intrusion using cone beam computed tomography. *PloS one* 2013;8:e60962.
27. Greenlee GM, Huang GJ, Chen SS, Chen J, Koepsell T, Hujuel P. Stability of treatment for anterior open-bite malocclusion: a meta-analysis. *Am J Orthod Dentofacial Orthop* 2011;139:154-69.