

# Early Class III Facemask Treatment with the Hybrid Hyrax and Alt-RAMEC Protocol

BENEDICT WILMES, DMD, PHD  
PETER NGAN, DMD  
ERIC J.W. LIOU, DDS, MS  
LORENZO FRANCHI, DDS, PHD  
DIETER DRESCHER, DMD, PHD

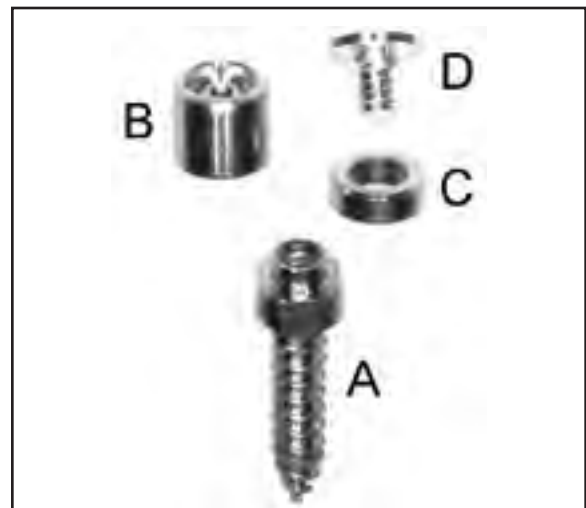
**Y**oung patients with Class III malocclusions and maxillary deficiencies are treated primarily with facemasks. Because the force is applied to the teeth, however, the inevitable mesial migration of the dentition can result in anterior crowding and the need for subsequent extraction therapy,<sup>1</sup> while the skeletal correction often turns out to be less effective than expected.<sup>1,2</sup> Various anchorage protocols have been proposed to overcome these drawbacks and transfer the force directly to the maxillary bone, including intentional ankylosis,<sup>3</sup> dental implants,<sup>4</sup> and surgical miniplates.<sup>5-8</sup> To minimize the surgical invasiveness of such techniques, Wilmes and colleagues introduced the Hybrid Hyrax, using mini-implants in the anterior palate for sagittal skeletal support.<sup>9-14</sup> Mini-implants with abutments are coupled with either deciduous or permanent molars to prevent mesial migration of the upper dentition.<sup>12,15</sup>

Facemask therapy is commonly combined with rapid palatal expansion (RPE) to take advantage of the expected stimulation of the midpalatal sutures (although there is some controversy regarding the effectiveness of this approach<sup>16,17</sup>). Liou's Alt-RAMEC (alternating rapid maxillary expansion and constriction) protocol was designed to maintain this sutural stimulation over a longer period, thus achieving greater maxillary protraction.<sup>18</sup> The expander is activated about 1mm (four turns) per day, alternating one week of expansion with one week of constriction. In the original protocol, this procedure was repeated for seven to nine weeks, using intraoral springs for the Class III correction. Franchi and colleagues proposed combining the Alt-RAMEC protocol with a facemask

anchored to deciduous teeth,<sup>19</sup> but this toothborne device carries the risk of periodontal damage and mesial dental migration. By contrast, the Hybrid Hyrax relies on skeletal anchorage from mini-implants in the anterior palate,<sup>20</sup> thus reducing the likelihood of periodontal damage, tipping, or loosening of the premolars or deciduous molars.<sup>12</sup>

## Treatment Protocol

After the application of topical or local anesthesia, two Benefit\* mini-implants (2mm × 9mm) with interchangeable abutments (Fig. 1A) are inserted with a contra-angle screwdriver next to



**Fig. 1 Hybrid Hyrax components used for anterior skeletal anchorage unit: A. Benefit mini-implant. B. Standard abutment. C. Hyrax Ring. D. Fixation screw for Hyrax Ring.**



Dr. Wilmes



Dr. Ngan



Dr. Liou



Dr. Franchi



Dr. Drescher

Dr. Wilmes is a Professor and Dr. Drescher is Professor and Head, Department of Orthodontics, University of Düsseldorf, Moorenstrasse 5, 40225 Düsseldorf, Germany. Dr. Ngan is Professor and Chair, Department of Orthodontics, School of Dentistry, West Virginia University, Morgantown, WV. Dr. Liou is Chairman, Faculty of Dentistry, and Assistant Professor, Institute of Craniofacial Medicine, Chang Gung Memorial Hospital, Taipei, Taiwan. Dr. Franchi is an Assistant Professor, Department of Surgery and Translational Medicine, University of Florence, Florence, Italy, and a Thomas M. Graber Visiting Scholar, Department of Orthodontics and Pediatric Dentistry, School of Dentistry, University of Michigan, Ann Arbor. Dr. Wilmes is also a Visiting Professor, Department of Orthodontics, University of Alabama at Birmingham School of Dentistry; he is the developer of the Benefit system. E-mail Dr. Wilmes at wilmes@med.uni-duesseldorf.de.

the midpalatal suture, in the area of the second and third palatal rugae (Fig. 2). Pre-drilling is not required in young patients due to the low mineralization rate of the bone. At the same appointment, bands are fitted to the upper second deciduous or first permanent molars. Transfer caps (Fig. 3) are added before a silicone impression is taken. Laboratory analogs (Fig. 4) are then placed over the transfer caps, bands are positioned in the impression, and a plaster cast is made.

Two standard Benefit abutments (Fig. 1B) are screwed over the laboratory analogs. A Hyrax\*\*-

\*PSM Medical Solutions, Tuttingen, Germany; www.psm.ms. Distributed in the U.S. by PSM North America, Indio, CA; www.psm-na.us.

\*\*Trademark of Dentaaurum, Inc., Newtown, PA; www.dentaaurum.com.

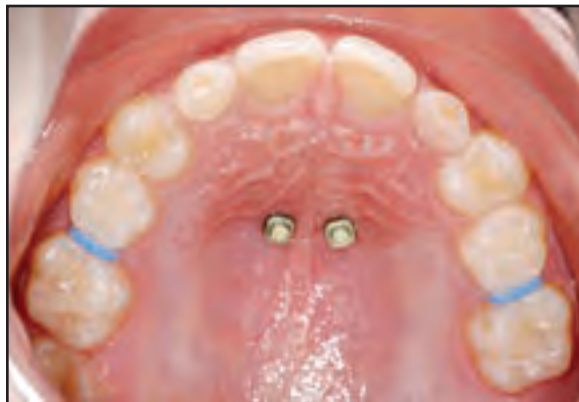

Fig. 2 Two mini-implants inserted near third palatal ruga. Temporary addition of silicon to inner threads makes mini-implant head slightly smoother, improving patient comfort until Hybrid Hyrax is affixed.

type palatal split screw is welded or soldered to the two anterior abutments and to the molar bands. Rigid .048" stainless steel sectional wires with hooks near the canines are welded or soldered to the buccal sides of the molar bands for the application of orthopedic protraction forces (Fig. 5).

The appliance can be fitted even if the two mini-implants are not absolutely parallel; the standard Benefit abutments (as shown in Case 1) simplify installation, since the fixation screws are integrated into the abutments. Alternatively, if

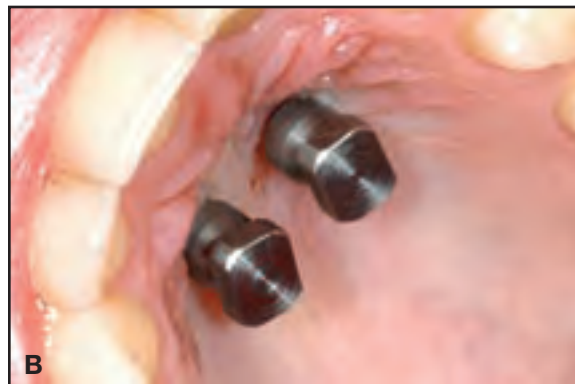

Fig. 3 Impression caps (A) placed over mini-implant heads (B).

Hyrax Rings\* (Fig. 1C), attached with small fixation screws (Fig. 1D), are used instead of the abutments (as shown in Case 2), minor errors in placement precision are easier to detect and correct.

The Hybrid Hyrax should be affixed to the mini-implants as soon as possible. A rough adaptation to the molars, using gentle pressure, is followed by a final adjustment of the molar bands. A light-cured cement\*\*\* is recommended to allow enough time for installation.

Immediately after insertion of the Hybrid Hyrax, the sagittal split screw should be activated for expansion by a 180° rotation twice a day, resulting in a daily activation of .8mm. After one week

\*PSM Medical Solutions, Tuttlingen, Germany; [www.psm.ms](http://www.psm.ms). Distributed in the U.S. by PSM North America, Indio, CA; [www.psm-na.us](http://www.psm-na.us).

\*\*\*Reliance Orthodontic Products, Itasca, IL; [www.relianceorthodontics.com](http://www.relianceorthodontics.com).

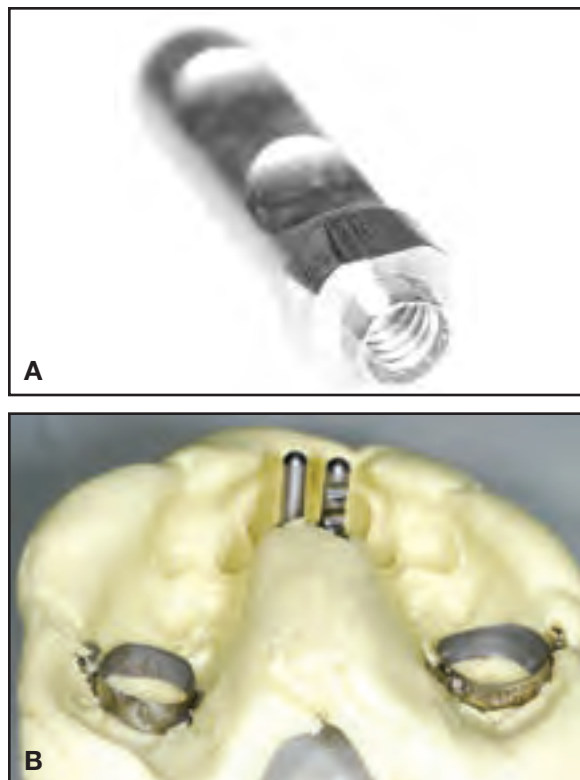


Fig. 4 Laboratory analog (A) positioned over impression cap (B) before addition of plaster.

of expansion, the screw is activated for compression for the next week. This procedure is repeated over seven or eight weeks, depending on the desired amount of expansion. At the same time, a protraction force of 400g is applied on each side from elastics connected to the facemask (Fig. 6).

This early Class III treatment usually takes about nine months. The mini-implants can then be removed without anesthesia.

### Case 1

A 7-year-old male presented with a severe Class III malocclusion, a Wits appraisal of -8.2mm, and no centric occlusion-centric relation

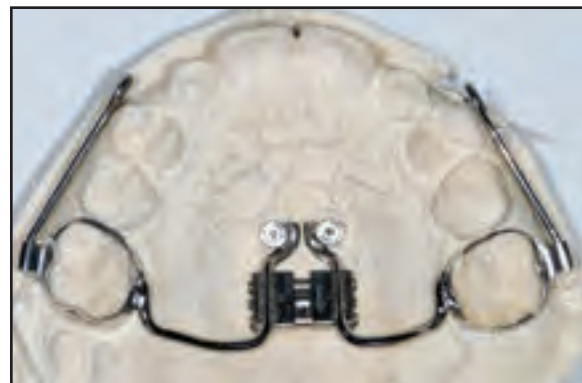

Fig. 5 Hybrid Hyrax with additional buccal wires on plaster cast.

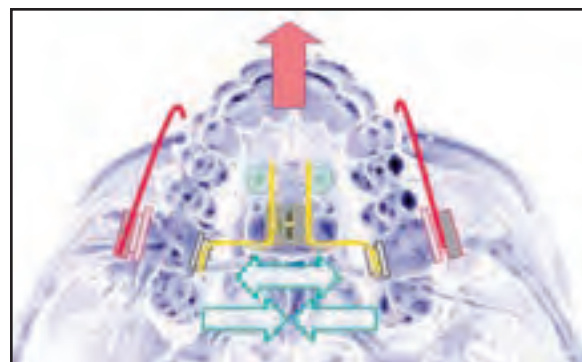


Fig. 6 Hybrid Hyrax and facemask combined with Alt-RAMEC (alternating rapid maxillary expansion and constriction) protocol for maxillary protraction.

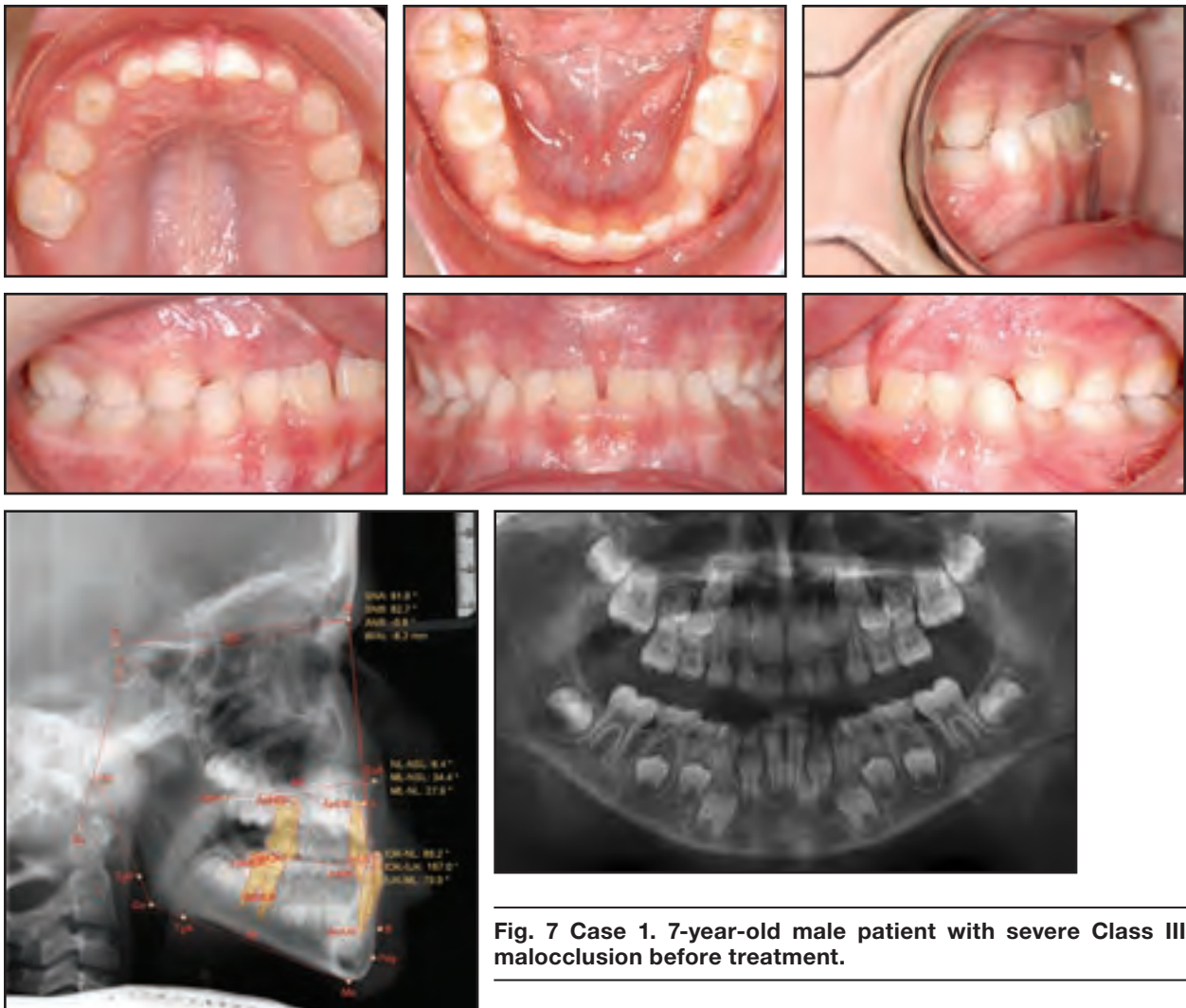
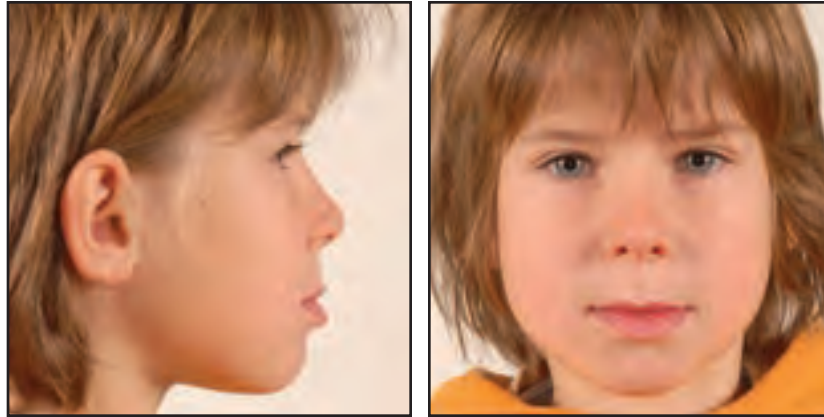

Fig. 7 Case 1. 7-year-old male patient with severe Class III malocclusion before treatment.

# Early Class III Facemask Treatment with the Hybrid Hyrax

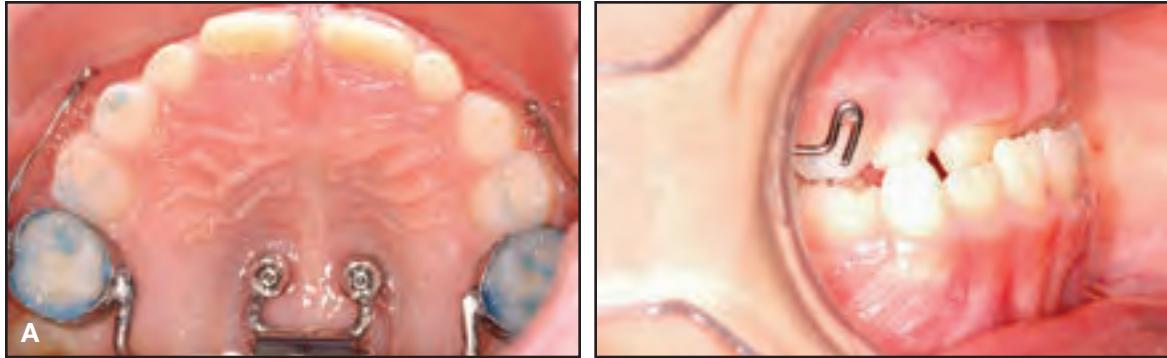


Fig. 8 Case 1. A. Hybrid Hyrax with added buccal sectional wires. B. Facemask adapted for maxillary protraction; removable plate placed in lower arch.

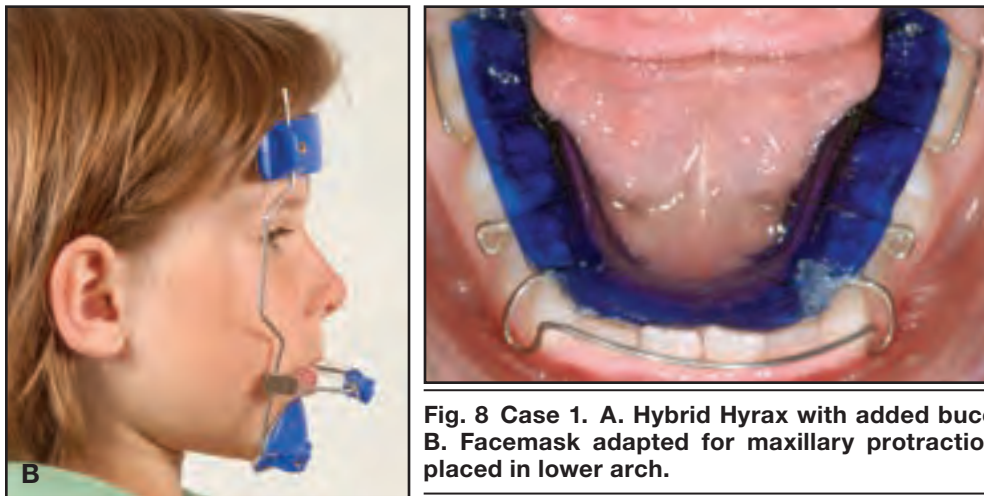


Fig. 9 Case 1. Upper arch after eight weeks of Alt-RAMEC treatment, ending with constriction phase.

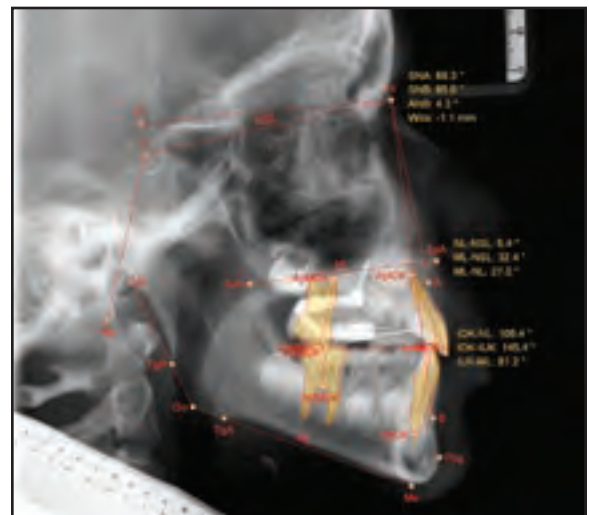


Fig. 10 Case 1. Maxilla sufficiently advanced after nine months of treatment.

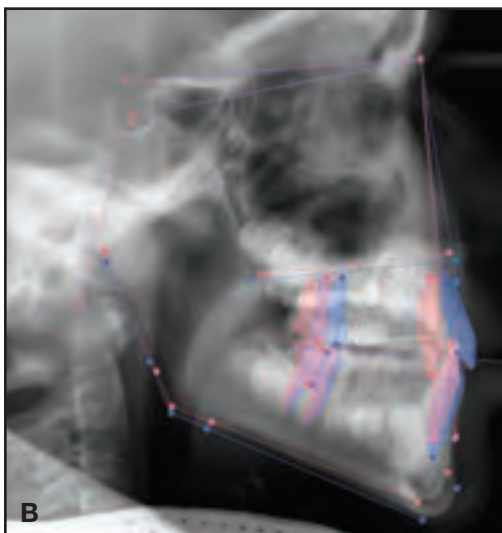
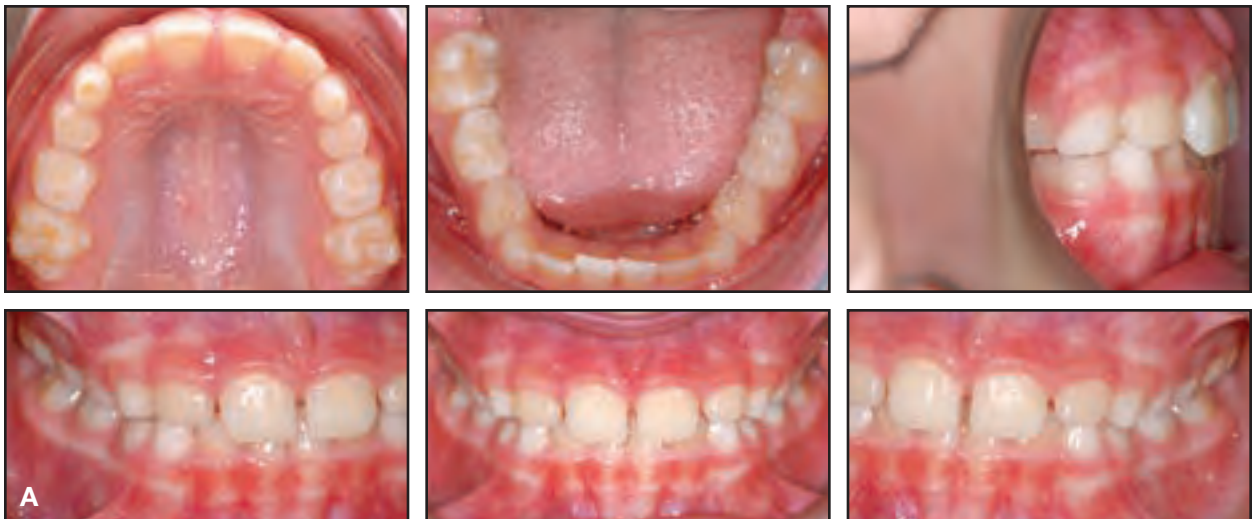

Fig. 11 Case 1. A. Patient after nine months of early Class III treatment. B. Superimposition of pre- and post-treatment cephalometric tracings.

# Early Class III Facemask Treatment with the Hybrid Hyrax

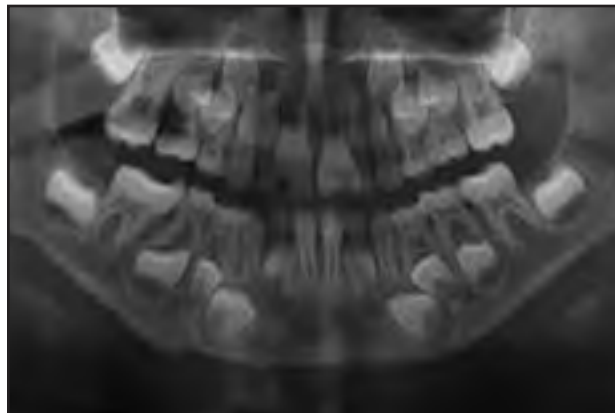
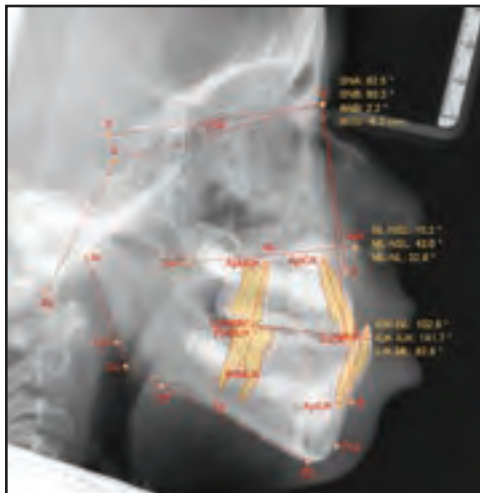
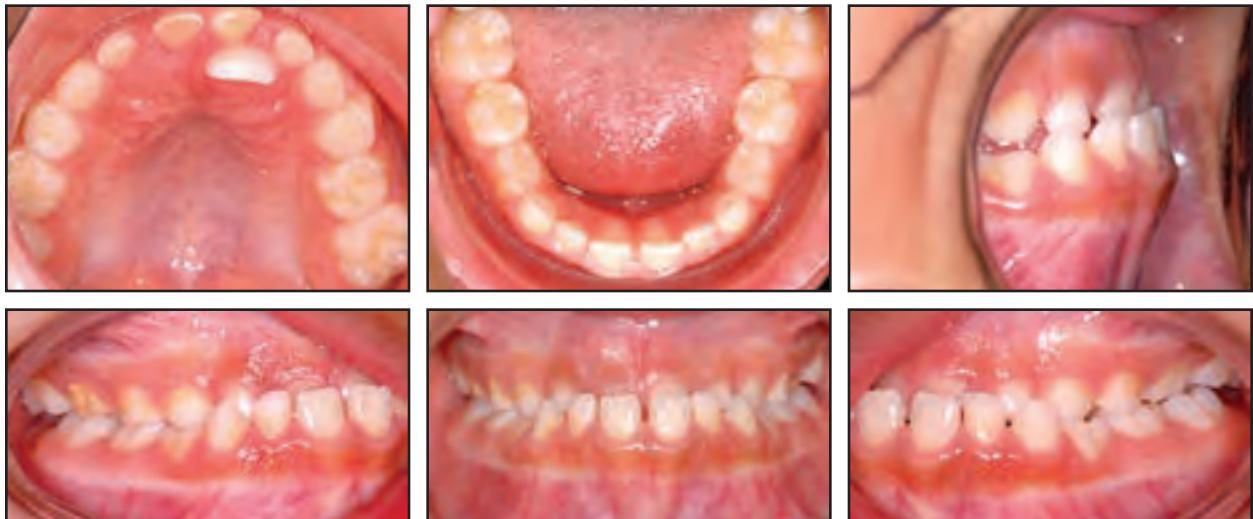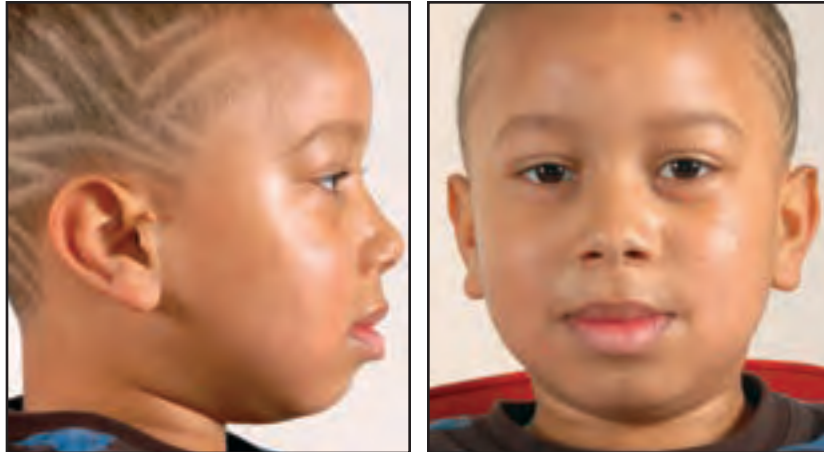


Fig. 12 Case 2. 8-year-old male patient with severe skeletal Class III malocclusion and mild centric occlusion-centric relation discrepancy before treatment.

(CO-CR) discrepancy (Fig. 7). A Hybrid Hyrax with additional buccal sectional wires was attached to the second deciduous molars and activated according to the Alt-RAMEC protocol (Fig. 8A). At the same appointment, a facemask was adapted for maxillary protraction, and a lower removable plate was fabricated to facilitate correction of the anterior crossbite (Fig. 8B).

The sagittal split screw was activated twice a day with 180° turns, for a daily activation of .8mm. A protraction force of 400g was applied on each side from elastics connected to the facemask. After one week of expansion, the split screw was reactivated for a week of compression. Since the maxilla was not too narrow, the Alt-RAMEC protocol was concluded in eight weeks with the fourth constriction phase (Fig. 9).

After nine months of this Phase I treatment, the maxilla was sufficiently advanced, and the Wits appraisal had improved to -1.1mm (Fig. 10). The Hybrid Hyrax was then removed, and a removable appliance was inserted for retention (Fig. 11).

### Case 2

An 8-year-old male presented with a severe skeletal Class III malocclusion, a Wits appraisal of -6.3mm, and a mild CO-CR discrepancy of 1mm (Fig. 12). The lingually erupted maxillary left central incisor tipped spontaneously into its proper position after extraction of the central deciduous incisors.

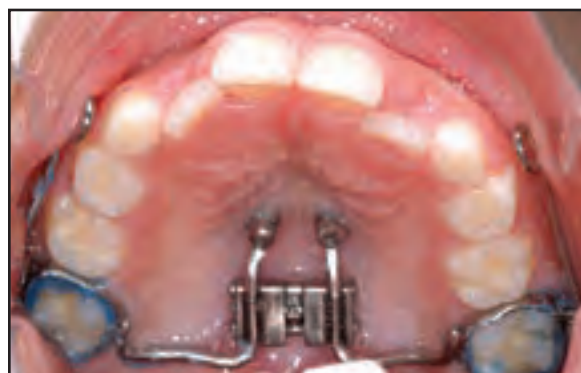

Fig. 13 Case 2. Hybrid Hyrax with added buccal sectional wires.

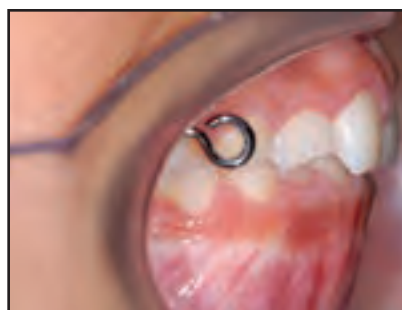
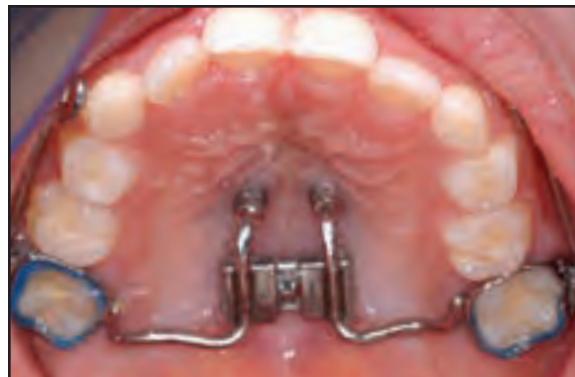
Fig. 14 Case 2. Improvement in overjet after eight weeks of treatment with Hybrid Hyrax and Alt-RAMEC protocol.

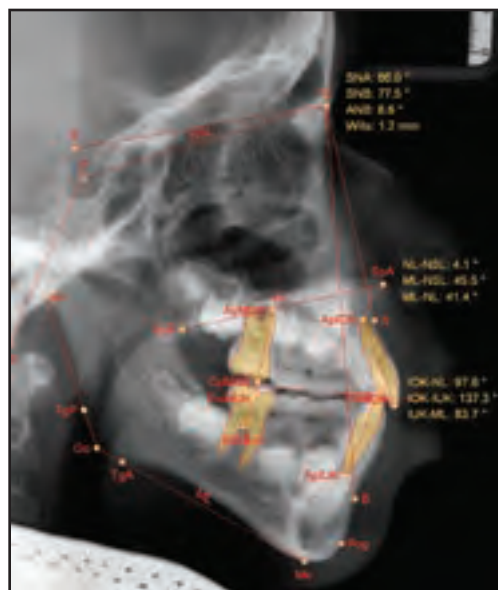

Fig. 15 Case 2. After nine months of treatment.



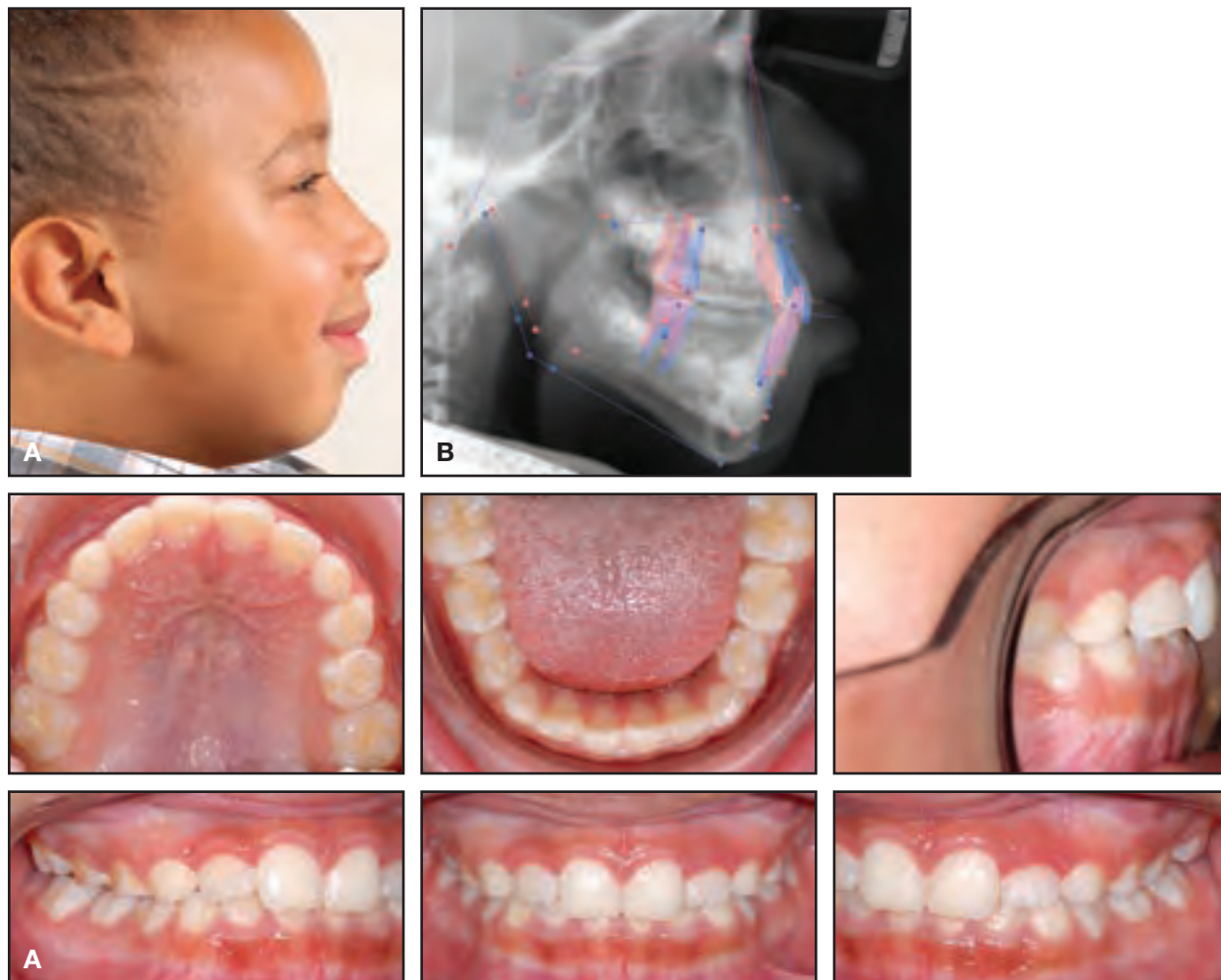
Eleven months later, a Hybrid Hyrax with additional buccal sectional wires was attached to the first permanent molars and activated according to the Alt-RAMEC protocol (Fig. 13). At the same appointment, a facemask was adapted for maxillary protraction (400g on each side). Only 1mm of maxillary expansion was required, and the Alt-RAMEC protocol ended in eight weeks with the fourth constriction activation (Fig. 14).

After nine months of Phase I treatment, the maxilla was sufficiently advanced, and the Wits appraisal had improved to 1.1mm (Fig. 15). The

Hybrid Hyrax was removed; a removable appliance was delivered for retention (Fig. 16).

### Discussion

As recommended by various authors, Class III treatment was started quite early in these two patients.<sup>17</sup> Although a facemask was used as extraoral anchorage for the protraction forces in both cases, a Mentoplate<sup>9</sup> or two Bollard mini-plates<sup>6</sup> may be used if the patient prefers intraoral devices.



**Fig. 16 Case 2. A. Patient after nine months of Phase I treatment. B. Superimposition of pre- and post-treatment cephalometric tracings.**

The anterior palate is our preferred location for mini-implant insertion because of its superior bone quality and thin, attached mucosa, resulting in a relatively low failure rate.<sup>21</sup> In addition, there is virtually no risk of tooth damage.

Considering the relatively short treatment time, both of the cases shown here demonstrated a substantial improvement in the Wits appraisal (7.1mm and 7.4mm). Similarly, Nienkemper and colleagues found an average improvement of 4.1mm in Wits values using the Hybrid Hyrax and facemask.<sup>15</sup> Further investigation of these effects is recommended.

## Conclusion

The combination of the Hybrid Hyrax, facemask, and Alt-RAMEC protocol offers the following advantages in early treatment of severe Class III cases:

- Because the sagittal forces are transferred to the maxillary bone, there are no dental side effects in terms of mesial migration.
- The transverse forces are applied anteriorly to mini-implants, with no risk of periodontal damage to the premolars or deciduous molars.
- Due to the opening of the midpalatal sutures, Alt-RAMEC provides a longer-lasting “RPE effect” for increased maxillary protraction.
- The treatment is minimally invasive.
- The upper and lower arches remain fully accessible for orthodontic corrections.

## REFERENCES

1. Williams, M.D.; Sarver, D.M.; Sadowsky, P.L.; and Bradley, E.: Combined rapid maxillary expansion and protraction facemask in the treatment of Class III malocclusions in growing children: A prospective long-term study, *Semin. Orthod.* 3:265-274, 1997.
2. Ngan, P.; Yiu, C.; Hu, A.; Hägg, U.; Wei, S.H.; and Gunel, E.: Cephalometric and occlusal changes following maxillary expansion and protraction, *Eur. J. Orthod.* 20:237-254, 1998.
3. Kokich, V.G.; Shapiro, P.A.; Oswald, R.; Koskinen-Moffett, L.; and Clarren, S.K.: Ankylosed teeth as abutments for maxillary protraction: A case report, *Am. J. Orthod.* 88:303-307, 1985.
4. Henry, P.J.: Clinical experiences with dental implants, *Adv. Dent. Res.* 13:147-152, 1999.
5. Kaya, D.; Kocadereli, I.; Kan, B.; and Tasar, F.: Effects of facemask treatment anchored with miniplates after alternate rapid maxillary expansions and constrictions: A pilot study, *Angle Orthod.* 81:639-646, 2011.
6. De Clerck, H.; Cevidanes, L.; and Baccetti, T.: Dentofacial effects of bone-anchored maxillary protraction: A controlled study of consecutively treated Class III patients, *Am. J. Orthod.* 138:577-581, 2010.
7. Sar, C.; Arman-Özçirpici, A.; Uçkan, S.; and Yazici, A.C.: Comparative evaluation of maxillary protraction with or without skeletal anchorage, *Am. J. Orthod.* 139:636-649, 2011.
8. Kircelli, B.H. and Pektas, Z.O.: Midfacial protraction with skeletally anchored face mask therapy: A novel approach and preliminary results, *Am. J. Orthod.* 133:440-449, 2008.
9. Wilmes, B.; Nienkemper, M.; Ludwig, B.; Kau, C.H.; and Drescher, D.: Early Class III treatment with a Hybrid Hyrax-Mentoplate combination, *J. Clin. Orthod.* 45:15-21, 2011.
10. Wilmes, B. and Drescher, D.: A miniscrew system with interchangeable abutments, *J. Clin. Orthod.* 42:574-580, 2008.
11. Wilmes, B.; Drescher, D.; and Nienkemper, M.: A miniplate system for improved stability of skeletal anchorage, *J. Clin. Orthod.* 43:494-501, 2009.
12. Wilmes, B.; Nienkemper, M.; and Drescher, D.: Application and effectiveness of a mini-implant- and tooth-borne rapid palatal expansion device: The Hybrid Hyrax, *World J. Orthod.* 11:323-330, 2010.
13. Wilmes, B.: Fields of application of mini-implants, in *Mini-Implants in Orthodontics: Innovative Anchorage Concepts*, ed. B. Ludwig, S. Baumgaertel, and S.J. Bowman, Quintessence Publishing Co., Hanover Park, IL, 2008, pp. 91-122.
14. Ludwig, B.; Glasl, B.; Bowman, S.J.; Drescher, D.; and Wilmes, B.: Miniscrew-supported Class III treatment with the Hybrid RPE Advancer, *J. Clin. Orthod.* 44:533-539, 2010.
15. Nienkemper, M.; Wilmes, B.; Pauls, A.; and Drescher, D.: Maxillary protraction using a Hybrid Hyrax-facemask combination, *Prog. Orthod.* 14:5, 2013.
16. Baccetti, T.; McGill, J.S.; Franchi, L.; McNamara, J.A. Jr.; and Tollaro, I.: Skeletal effects of early treatment of Class III malocclusion with maxillary expansion and face-mask therapy, *Am. J. Orthod.* 113:333-343, 1998.
17. Jager, A.; Braumann, B.; Kim, C.; and Wahner, S.: Skeletal and dental effects of maxillary protraction in patients with Angle Class III malocclusion: A meta-analysis, *J. Orofac. Orthop.* 62:275-284, 2001.
18. Liou, E.J.: Effective maxillary orthopedic protraction for growing Class III patients: A clinical application simulates distraction osteogenesis, *Prog. Orthod.* 6:154-171, 2005.
19. Franchi, L.; Baccetti, T.; Masucci, C.; and Defraia, E.: Early Alt-RAMEC and facial mask protocol in Class III malocclusion, *J. Clin. Orthod.* 45:601-609, 2011.
20. Ludwig, B.; Baumgaertel, S.; Zorkun, B.; Bonitz, L.; Glasl, B.; Wilmes, B.; and Lisson, J.: Application of a new viscoelastic finite element method model and analysis of miniscrew-supported Hybrid Hyrax treatment, *Am. J. Orthod.* 143:426-435, 2013.
21. Karagkiolidou, A.; Ludwig, B.; Pazera, P.; Gkantidis, N.; Pandis, N.; and Katsaros, C.: Survival of palatal miniscrews used for orthodontic appliance anchorage: A retrospective cohort study, *Am. J. Orthod.* 143:767-772, 2013.