

Wear-time recording during early Class III facemask treatment using TheraMon chip technology

Bruce Stocker,^a Jan H. Willmann,^b Benedict Wilmes,^c Sivabalan Vasudavan,^d and Dieter Drescher^e
Düsseldorf, Germany, and Cambridge, Mass

Successful intervention in a developing Class III malocclusion with facemask protraction therapy depends on a patient's ability to adhere to the recommendations for duration of appliance wear. In this article, we report the introduction of a novel approach for tracking of the duration of application of a protraction facemask, with the incorporation of a "FaceMon" sensor (TheraMon, microelectronic system; MC Technology GmbH, Hargelsberg, Austria) to track wear time. A 9-year-old boy with a Class III malocclusion was successfully treated with a modified alternate rapid maxillary expansion and constriction protocol and intermittent application of a hybrid hyrax-protraction facemask combination. The average duration of wear of the facemask was measured at 10.8 hours per day. The use of an objective measuring device may have implications for the development of treatment strategies, since patient responses may be able to calibrated in relation to compliance. (*Am J Orthod Dentofacial Orthop* 2016;150:533-40)

Compliance in orthodontics refers to how reliably a patient adheres to the prescribed instructions of the orthodontist and is an important key to achieving a successful treatment outcome.¹ Compliance is influenced by many factors including the personality of the patient, the comfort of wear of an appliance, and parental support.¹

The literature is replete with studies that have evaluated the effectiveness of interceptive Class III orthodontic treatment in adolescent patients. However, no study has evaluated the patient's compliance objectively. The current literature shows that one cannot rely on subjective assessments of compliance; ie, patient reports or

questionnaires.² Objective compliance measurement using a sensor (TheraMon, microelectronic system; MC Technology GmbH, Hargelsberg, Austria) has only been described for intraoral appliances. The conventional approach to addressing a Class III malocclusion with maxillary retrognathia in an adolescent patient is with a protraction facemask in conjunction with a rapid maxillary expansion appliance. The corollary of this approach is an inevitable mesial migration of the dentition, resulting in the development of anterior crowding and increasing the possible need for subsequent extraction therapy.³

The mesial migration of the molars, or loss of anchorage, can be mitigated using different kinds of additional anchorage protocols, such as intentionally ankylosed teeth,⁴ dental implants,⁵ or miniplates.⁶⁻⁸ Another advantage of these approaches is that orthopedic forces may be directly transferred to the nasomaxillary complex.

Wilmes et al⁹⁻¹³ and Ludwig et al¹⁴ introduced a hybrid hyrax appliance to minimize anchorage loss, involving a minimally surgically invasive procedure. Two mini-implants are inserted in the paramedian area of the anterior palate, serving to support the anchorage in the sagittal and transverse dimension.¹⁵ The maxillary molars can be stabilized in their position while orthopedically displacing the maxilla anteriorly. In the transverse plane, the mini-implants reduce the forces acting on the

^aInstructor, Department of Orthodontics, University of Düsseldorf, Düsseldorf, Germany.

^bAssistant professor, Department of Orthodontics, University of Düsseldorf, Düsseldorf, Germany.

^cProfessor, Department of Orthodontics, University of Düsseldorf, Düsseldorf, Germany.

^dVisiting lecturer, Department of Developmental Biology, Harvard School of Dental Medicine, Cambridge, Mass.

^eProfessor and head, Department of Orthodontics, University of Düsseldorf, Düsseldorf, Germany.

All authors have completed and submitted the ICMJE Form for Disclosure of Potential Conflicts of Interest, and none were reported.

Address correspondence to: Jan H. Willmann, Department of Orthodontics, University of Düsseldorf, Moorenstr. 5, Düsseldorf 40225, Germany; e-mail, Jan.Willmann@med.uni-duesseldorf.de.

Submitted, July 2015; revised and accepted, April 2016.

0889-5406/\$36.00

© 2016 by the American Association of Orthodontists. All rights reserved.

<http://dx.doi.org/10.1016/j.ajodo.2016.04.016>

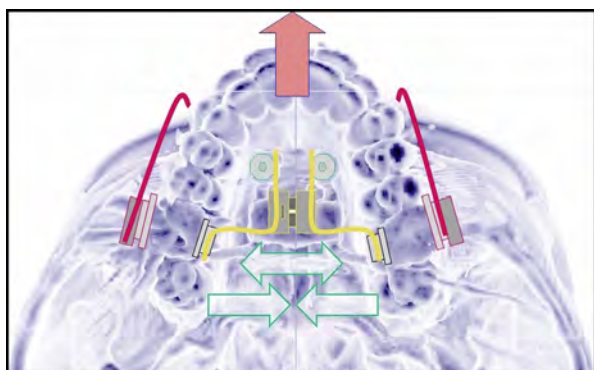


Fig 1. Principle of the hybrid hyrax-facemask-Alt-RAMEC protocol: alternating expansion and constriction for protraction of the maxilla.

dentition during maxillary expansion, thereby possibly leading to less buccal tipping, root damage, and gingival dehiscence.^{9-14,16}

Protraction facemask therapy is often combined with orthopedic expansion of the maxilla.¹⁷⁻¹⁹ To increase the stimulatory effect of the midface sutures, Liou et al²⁰ described a method of alternating expansion and constriction. In this protocol, protraction of the maxilla starts after 7 to 8 weeks of alternating expansion and constriction of 1 mm each day.

We modified the protocol in the way that we started maxillary protraction simultaneously with the alternating expansions and constrictions (Fig 1).

For Class III correction, 2 intraoral elastics with a force of 400 g per side were applied, as measured with a Dynamometer (Correx, Köniz, Switzerland).

The recommended time duration for wear of the facemask varies with differing early Class III treatment protocols, ranging from 14 hours²¹ per day to full-time wear.¹⁷ However, none of these studies has reported the effective duration of wear time in subjects but rather has relied on self-reporting from patients and parents. In this case report, we used the TheraMon chip (TheraMon microelectronic system; MC Technology GmbH) integrated into a facemask to objectively document the compliance of our patient (Fig 2). Schott et al²² showed that wear-time documentation is well accepted by patients and parents.

DIAGNOSIS AND ETIOLOGY

A 9-year-old boy was referred to the Department of Orthodontics of the University of Düsseldorf in Germany by his general dental practitioner for treatment of his anterior crossbite. The extraoral examination

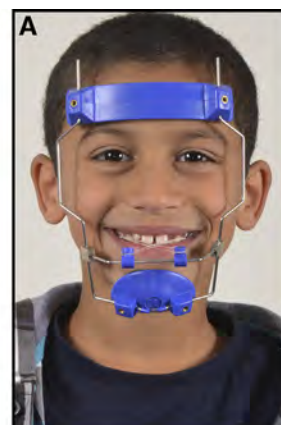

Fig 2. A, Facemask; B, location of the TheraMon chip.

showed a concave facial profile and a retrusive midface (Fig 3).

The intraoral examination showed an Angle Class III malocclusion characterized by molar and canine relations of a half unit mesial occlusion bilaterally. Overjet was -2.6 mm, and overbite was -0.5 mm. The patient had both anterior and posterior crossbites. Transverse measurements of the dental arch showed no discrepancy between the maxillary and mandibular arches. Thus, the posterior crossbite was due to the sagittal skeletal discrepancy. The dental midline was coincident with the facial midline. A maxillary midline diastema was present with retained deciduous lateral incisors. A retained hypoplastic deciduous lateral incisor was present in the mandibular arch. The panoramic radiograph showed agenesis of the mandibular right lateral incisor, developing mandibular third molars, an ectopically positioned mandibular right canine, pipette-like roots, and deep antegonial notching of the mandible (Fig 4). The pretreatment lateral cephalometric analysis showed a distinct skeletal Class III malocclusion (Wits appraisal, -5.5 mm; ANB, -1.4°) with a retrognathic maxilla (SNA, 73.0°) and a slightly retrognathic mandible (SNB, 74.4°) with a vertical facial structure (ML/NL, 32.4°).

The functional analysis showed an anterior mandibular shift of 1 mm caused by premature interference of the mandibular deciduous canines. Additionally, the patient demonstrated an anterior tongue thrust habit.

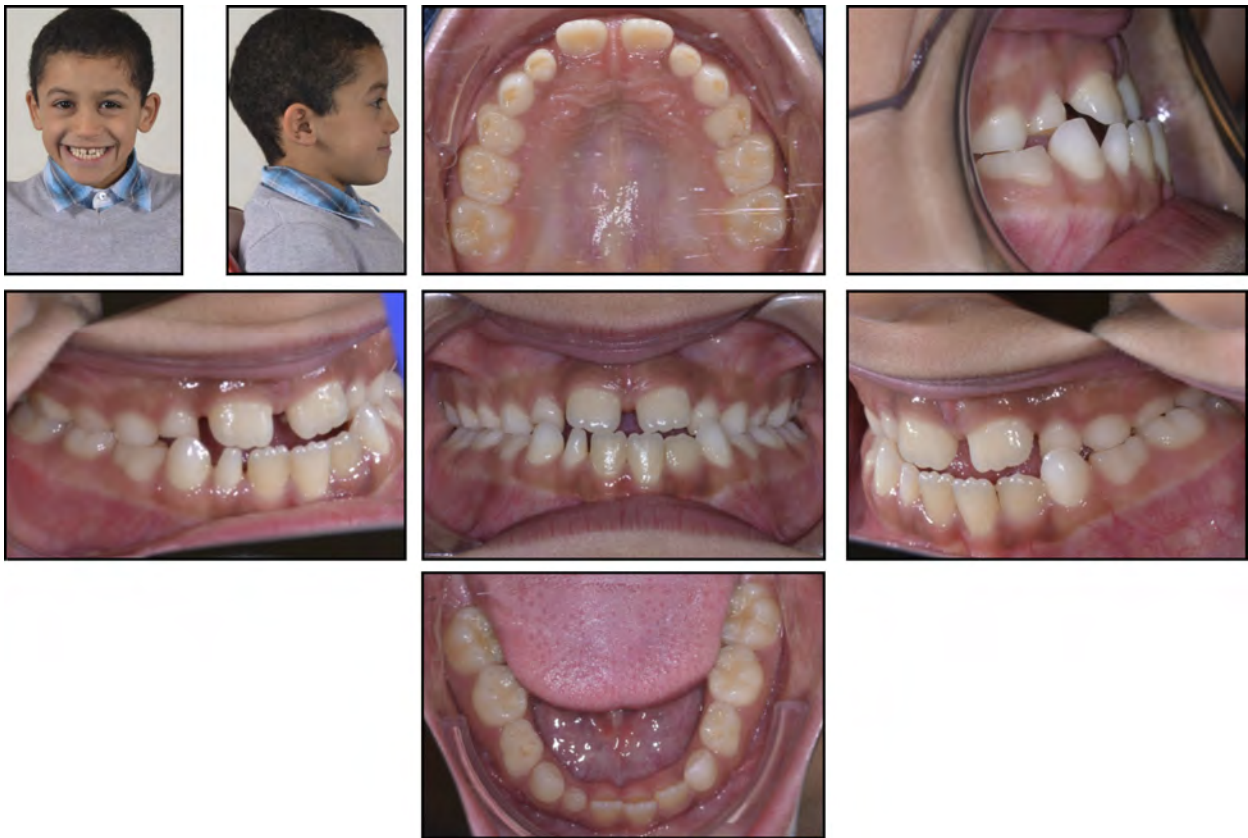

Fig 3. A 9-year-old boy with a severe Class III malocclusion.

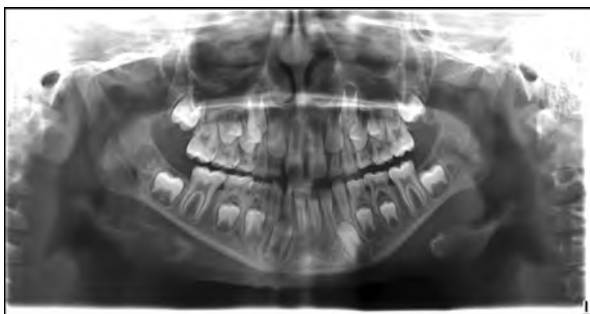


Fig 4. Panoramic radiograph.

TREATMENT OBJECTIVES

The specific treatment objectives included (1) early treatment with maxillary protraction using the modified Alt-RAMEC protocol to correct the skeletal maxillary deficiency (Fig 1), (2) correction of the anterior crossbite and elimination of the functional mandibular shift, (3) overcorrection into a dental Class II relationship and subsequent distalization of the maxillary first molars into a Class I occlusion, and (4) elimination of the tongue thrust habit.

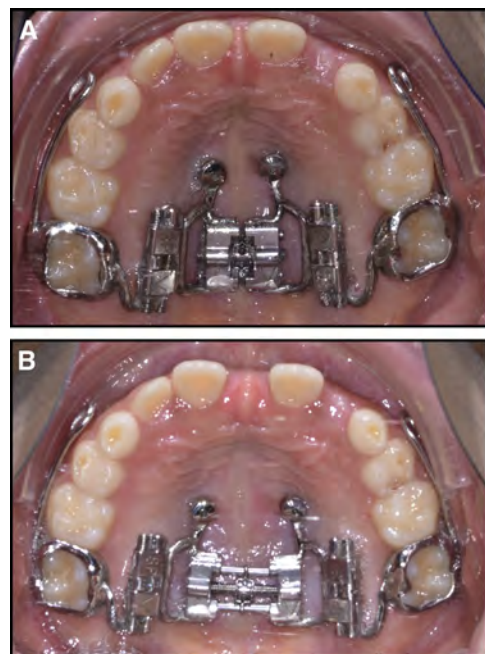


Fig 5. Hybrid hyrax distalizer: **A**, in situ before expansion; **B**, after expansion.

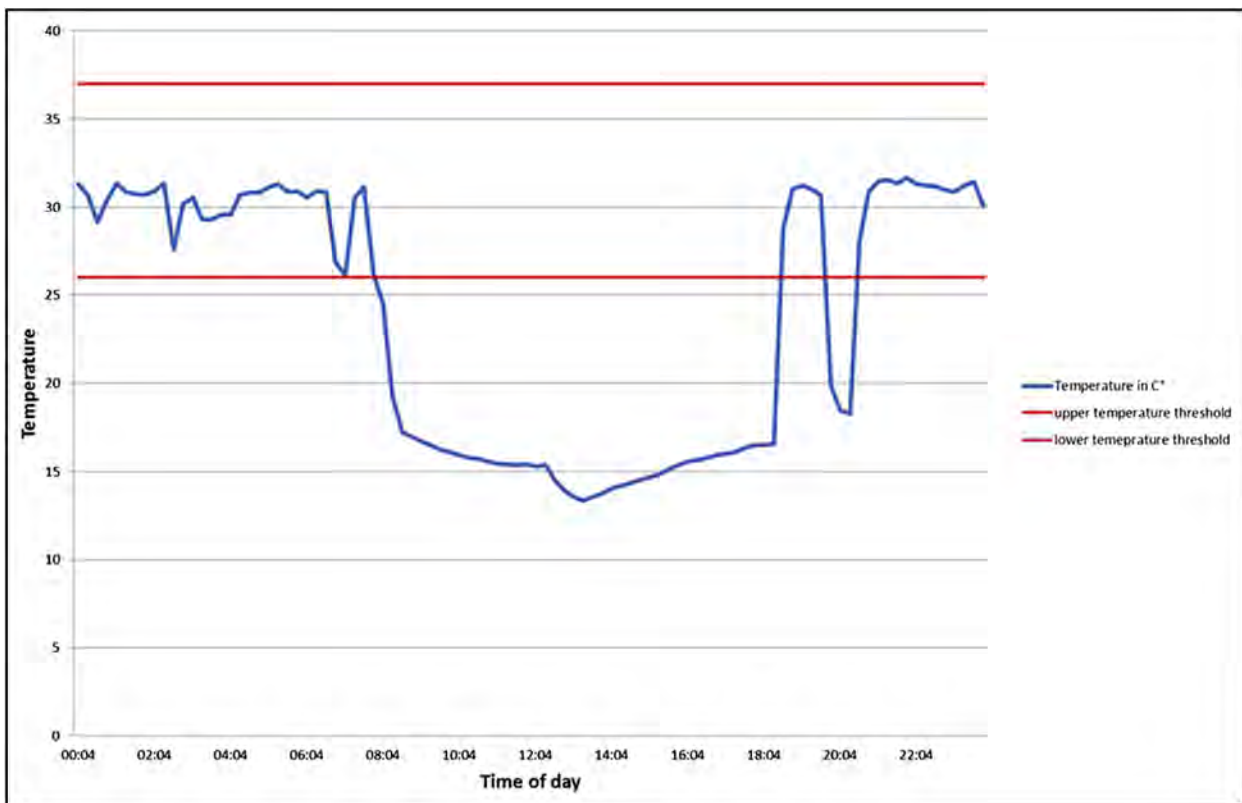


Fig 6. Temperature change during 24 hours.

The treatment plan did not yet include space management of the aplastic mandibular right lateral incisor.

TREATMENT ALTERNATIVES

Orthopedic protraction of the maxilla can be achieved using either an extraoral appliance such as a protraction facemask or intraoral skeletal anchorage such as Bollard⁷ plates or a Mentoplate.⁹ The relative merits, shortcomings, and risks of each treatment modality were clearly explained to the patient and his parents. They made an informed decision to proceed with treatment using the protraction facemask, secondary to their underlying concerns about the associated surgical risks.

Other possible treatment alternatives included a functional appliance such as the Fränkel III, which is considered less invasive but perhaps also less effective in correcting a retrognathic maxilla, since its treatment effects are mainly dentoalveolar and due to downward and backward rotation of the mandible.²³

The degree of compliance could be assessed with self-reporting mechanisms: eg, patient and parent questionnaires rather than a microelectronic device.

However, this approach is susceptible to recall bias, and compliance cannot be judged objectively.

TREATMENT PROTOCOL

Topical and local anesthetics were applied. Two mini-implants with exchangeable abutments (2 × 9 mm, Benefit System; PSM Medical Solutions, Tuttlingen, Germany) were inserted with a contra-angle screwdriver next to the midpalatal suture and adjacent to the third palatal rugae. Because of the low mineralization of the bones in young patients, predrilling was not necessary.²⁴ Impression caps were fitted onto the implants, and a silicone impression was taken. Bands were not fitted to the molars because the hybrid hyrax distalizer, including the buccal extension arms, was cast in 1 piece.²⁴ The appliance comprised a split palatal screw (hyrax; Dentaurem, Ispringen, Germany) with a thread pitch of 0.2 mm.

The appliance was placed 1 week later, with the appliance bonded with Fuji ORTHO BAND (GC Corporation, Tokyo, Japan). This patient was treated with the modified Alt-RAMEC protocol comprising 15 weeks of alternating expansions and constrictions of 1 mm per day for 7 days, and concomitant protraction

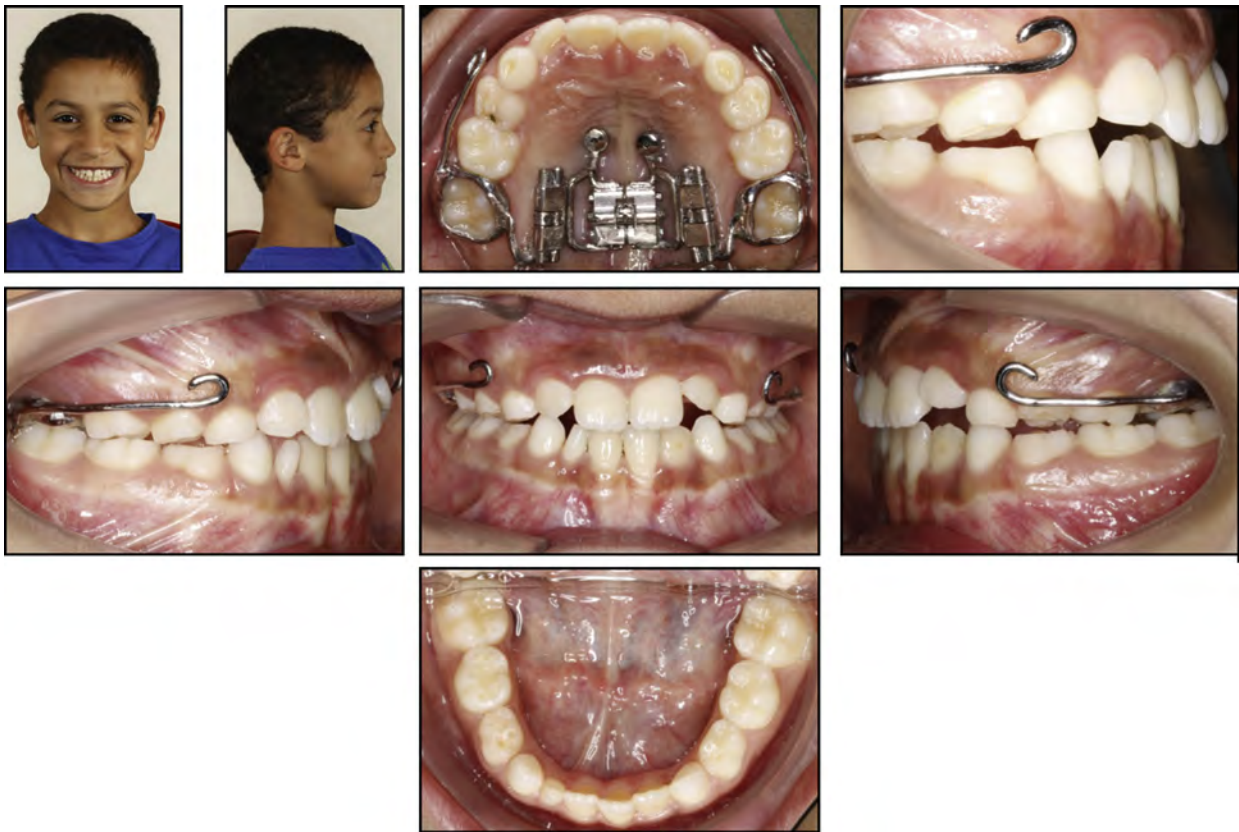

Fig 7. Photographs after 9 months of facemask treatment.

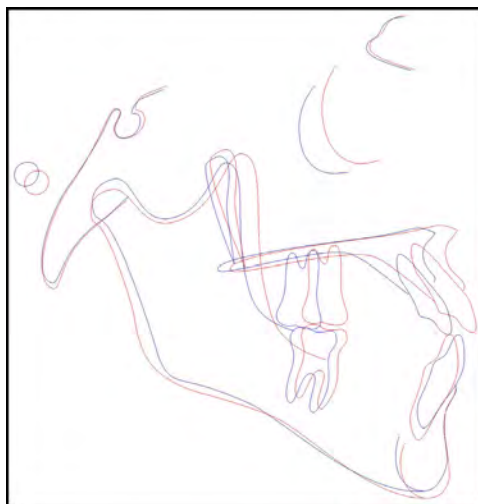

Fig 8. Superimposition of the tracings at pretreatment (blue line) and after 5 months of protraction (red line) (SN line at S).

of the maxilla by wearing the facemask (Figs 1 and 2, A). The magnitude of force applied was 400 g per side with the 5/16-in, 16-oz elastics. The hybrid hyrax distalizer

Table. Cephalometric values

	T0	T1	T2
SNA (°)	73.0	76.5	77.8
SNB (°)	74.4	74.6	75.0
ANB (°)	-1.4	2.0	2.8
Wits appraisal (mm)	-5.5	-1.9	-1.6
NSBa (°)	137.3	135.8	134.6
NL-NSL (°)	13.2	10.8	11.6
ML-NSL (°)	45.6	44.5	46.3
ML-NL (°)	32.4	33.7	34.7
ArGoMe (°)	140.4	132.4	134.5
U1-NL (°)	119.3	113.2	114.0
L1-ML (°)	87.6	79.2	79.0
Interincisal angle (°)	120.6	133.9	132.3
Overjet (mm)	-2.6	3.5	5.1
Overbite (mm)	-0.5	-0.5	+0.5

T0, Pretreatment; T1, after the Alt-RAMEC period; T2, after 5 months of protraction.

facilitates both orthopedic advancement of the maxilla and a simultaneous orthodontic distalization of the maxillary molars (Fig 5, A and B). The elastics were attached from the hooks of the hybrid hyrax distalizer (Fig 5) to the support bar of the facemask in a downward

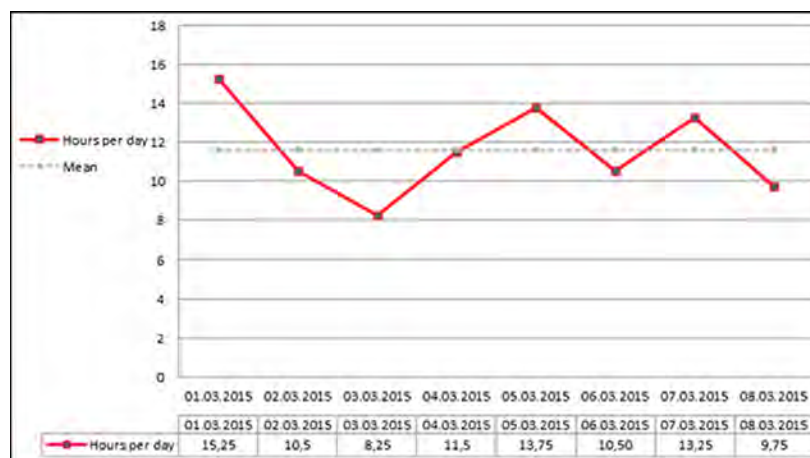


Fig 9. One week's wear times: mean hours per day.

and forward direction of 30° relative to the occlusal plane to reduce the anterior rotation of the maxilla.²⁵

The expansion and constriction were performed by activating the split screw by 90° at a rate of 5 times (0.2 mm/turn) a day.

The TheraMon chip consists of 2 parts: a battery and a temperature sensor. The ambient temperature is measured and recorded every 15 minutes. The collected data are transferred to the computer via a wireless docking station, and the TheraMon software calculates and draws a wear-time graph. The raw data of each measurement cycle can also be extracted from the software for scientific purposes. The wear-time graph can be printed and handed to the patient at each appointment; this seems to have a positive effect on patient adherence.²⁶

The TheraMon chip was integrated into the frontal support bar of the facemask (Fig 2, A and B). To integrate the sensor, the foam pad was removed from the support bar with a scalpel. A pit was milled into the bar (10 × 14 mm) to incorporate the sensor. The foam pad was then reattached to the facemask bar. Since the TheraMon chip is commonly used for intraoral appliances, the temperature thresholds had to be adapted to the expected extraoral environment. For intraoral use, the thresholds are between 31°C and 38°C. For extraoral use, the limits were set at 26°C to 37°C in the TheraMon software (Fig 6).

The patient was instructed to wear the facemask 16 hours per day. The first review appointment was 3 days after insertion of the appliance to assess whether the opening of the midpalatal suture occurred as expected. The patient was then reviewed weekly during the first month of protraction treatment and once a month thereafter until the Alt-RAMEC period was

finished. Subsequently, maxillary protraction was continued for a further 5 months. After completion of the protraction therapy, the appliance was left in place to allow later distalization of the maxillary first molars. Additionally, the patient received myofunctional therapy to address the tongue thrust.

TREATMENT RESULTS

Over a period of 9 months, the overjet relationship changed from a baseline value of -2.6 mm to +5.1 mm (Fig 7), with a net anterior displacement of 7.7 mm. SNA changed by +4.8°, from 73.0° to 77.8°, and the Wits appraisal changed by +3.9 mm, from -5.5 mm to -1.6 mm. The maxilla rotated anteriorly by 1.6° from 13.2° to 11.6° (NL-NSL) (Fig 8). Other skeletal changes were as shown in the Table.

The recording of the TheraMon chip showed a mean wear time of 10.8 hours per day. The maximum wear time was 19.2 hours per day. The protraction facemask was applied for at least 8 hours per day nearly 90% of the time over the 9 months. Figure 9 shows the daily wear time of a randomly selected week during the protraction phase.

DISCUSSION

This case report is the first article that describes a method to assess the wear time of a protraction facemask in an early Class III interceptive treatment protocol. Our data suggest that the TheraMon device can be favorably incorporated into a facemask. The temperature thresholds we set for the extraoral application of the sensor provided plausible data. The use of the TheraMon device might be limited in regions of the world where ambient temperatures reach the

thresholds set for the TheraMon chip. The contemporary protocols with the recommended duration of application are primarily based on clinical experience. Most authors recommend that patients should wear the protraction facemask from 14 to 24 hours per day.^{17,27,28}

The ability to objectively measure the duration of application of the protraction facemask, thereby assessing a patient's compliance, assists in the determination of the effectiveness of the treatment protocol.^{17,21,27,28} Slakter et al²⁹ introduced a subjective patient cooperation scale, where the clinician asked the patient's parents how long the appliance had been worn. Compliance was then appraised by means of a 3-point Likert scale (poor, moderate, good). It is assumed that microelectronic wear-time recording delivers more reliable data than do parental statements, which can be subject to recall bias.^{22,30}

Our 9-year-old patient had a mean wear time of 10.8 hours per day, which was less than the prescribed 16 hours. The maxilla was displaced anteriorly, with the SNA angle increasing by 4.8° (from 73.0° to 77.8°) and the Wits appraisal by 3.9 mm (from -5.5 to -1.6 mm), which is within the range of skeletal changes produced by facemask therapy reported in the literature.^{27,28} The maxilla rotated anteriorly (Δ ML-NSL, 1.6°) because the eccentric force vector did not pass through the center of resistance.

For removable appliances, Schott and Ludwig³¹ showed a median wear time of 9 hours per day, which did not coincide with the prescribed wear time of 12 to 15 hours. This observation corresponds with other studies, which showed that most patients do not comply with longer wear-time prescriptions.^{22,32}

Of course, further prospective clinical studies will be necessary to determine the optimum facemask wear time. With the addition of microelectronic wear-time recording devices, judgment on treatment protocols that rely on a patient's compliance may become more conclusive.¹⁹

CONCLUSIONS

The integration of the TheraMon sensor into the facemask provided sufficient data on the compliance of our patient and important insight into the adherence to prescribed instructions. There is a need for further investigation to determine the optimum duration of application of the protraction facemask, and the efficacy and efficiency of varying protocols. The incorporation of a microelectronic recording device, enables objective assessment of varying treatment protocols that depend on a patient's compliance.

REFERENCES

1. Witt E, Bartsch A, Sahn G, Schneider S. Determinanten des Trageverhaltens bei der Behandlung mit herausnehmbaren kieferorthopädischen Geräten. *Fortschr Kieferorthop* 1992;53:322-9.
2. Lee SJ, Ahn SJ, Kim TW. Patient compliance and locus of control in orthodontic treatment: a prospective study. *Am J Orthod Dentofacial Orthop* 2008;133:354-8.
3. Williams MD, Sarver DM, Sadowsky PL, Bradley E. Combined rapid maxillary expansion and protraction facemask in the treatment of Class III malocclusions in growing children: a prospective long-term study. *Semin Orthod* 1997;3:265-74.
4. Kokich VG, Shapiro PA, Oswald R, Koskinen-Moffett L, Clarren SK. Ankylosed teeth as abutments for maxillary protraction: a case report. *Am J Orthod* 1985;88:303-7.
5. Henry PJ. Clinical experiences with dental implants. *Adv Dent Res* 1999;13:147-52.
6. Kaya D, Kocadereli I, Kan B, Tasar F. Effects of facemask treatment anchored with miniplates after alternate rapid maxillary expansions and constrictions; a pilot study. *Angle Orthod* 2011;81:639-46.
7. De Clerck H, Cevidanes L, Baccetti T. Dentofacial effects of bone-anchored maxillary protraction: a controlled study of consecutively treated Class III patients. *Am J Orthod Dentofacial Orthop* 2010;138:577-81.
8. Sar C, Arman-Ozcirpici A, Uckan S, Yazici AC. Comparative evaluation of maxillary protraction with or without skeletal anchorage. *Am J Orthod Dentofacial Orthop* 2011;139:636-49.
9. Wilmes B, Nienkemper M, Ludwig B, Kau CH, Drescher D. Early Class III treatment with a hybrid hyrax-mentoplate combination. *J Clin Orthod* 2011;45:1-7.
10. Wilmes B, Drescher D. A miniscrew system with interchangeable abutments. *J Clin Orthod* 2008;42:574-80.
11. Wilmes B, Drescher D, Nienkemper M. A miniplate system for improved stability of skeletal anchorage. *J Clin Orthod* 2009;43:494-501.
12. Wilmes B, Nienkemper M, Drescher D. Application and effectiveness of a mini-implant- and tooth-borne rapid palatal expansion device: the hybrid hyrax. *World J Orthod* 2010;11:323-30.
13. Wilmes B, Bowman JS, Baumgaertel S. Fields of application of mini-implants. In: Ludwig B, Baumgaertel S, Bowman JS, editors. *Mini-implants in orthodontics. Innovative anchorage concepts. London, United Kingdom: Quintessence; 2008. p. 91-122.*
14. Ludwig B, Glas B, Bowman SJ, Drescher D, Wilmes B. Miniscrew-supported Class III treatment with the hybrid RPE advancer. *J Clin Orthod* 2010;44:533-9.
15. Nienkemper M, Wilmes B, Pauls A, Drescher D. Maxillary protraction using a hybrid hyrax-facemask combination. *Prog Orthod* 2013;14:1-8.
16. Nienkemper M, Pauls A, Ludwig B, Wilmes B, Drescher D. Preprosthetic molar uprighting using skeletal anchorage. *J Clin Orthod* 2013;47:433-7.
17. Baccetti T, McGill JS, Franchi L, McNamara JA Jr, Tollaro I. Skeletal effects of early treatment of Class III malocclusion with maxillary expansion and face-mask therapy. *Am J Orthod Dentofacial Orthop* 1998;113:333-43.
18. Jäger A, Braumann B, Kim C, Wahner S. Skeletal and dental effects of maxillary protraction in patients with Angle Class III malocclusion: a meta-analysis. *J Orofac Orthop* 2001;62:275-84.
19. Foersch M, Jacobs C, Wriedt S, Hechtner M, Wehrbein H. Effectiveness of maxillary protraction using facemask with or without maxillary expansion: a systematic review and meta-analysis. *Clin Oral Investig* 2015;19:1181-92.

20. Liou EJ. Effective maxillary orthopedic protraction for growing Class III patients: a clinical application simulates distraction osteogenesis. *Prog Orthod* 2005;6:154-71.
21. Westwood PV, McNamara JA Jr, Baccetti T, Franchi L, Sarver DM. Long-term effects of Class III treatment with rapid maxillary expansion and facemask therapy followed by fixed appliances. *Am J Orthod Dentofacial Orthop* 2003;123:306-20.
22. Schott TC, Schrey S, Walter J, Glasl BA, Ludwig B. Questionnaire study of electronic wear-time tracking as experienced by patients and parents during treatment with removable orthodontic appliances. *J Orofac Orthop* 2013;74:217-25.
23. Baik HS, Jee SH, Lee KJ, Oh TK. Treatment effects of Fränkel functional regulator III in children with Class III malocclusions. *Am J Orthod Dentofacial Orthop* 2004;125:294-301.
24. Wilmes B, Ludwig B, Katyal V, Nienkemper M, Rein A, Drescher D. The hybrid hyrax distalizer, a new all-in-one appliance for rapid palatal expansion, early class III treatment and upper molar distalization. *J Orthod* 2014;41(Suppl 1):S47-53.
25. Ngan PW, Hägg U, Yiu C, Wei SH. Treatment response and long-term dentofacial adaptations to maxillary expansion and protraction. *Semin Orthod* 1997;3:255-64.
26. Ackerman MB, Thornton B. Posttreatment compliance with removable maxillary retention in a teenage population: a short-term randomized clinical trial. *Orthodontics (Chic.)* 2010;12:22-7.
27. Nienkemper M, Wilmes B, Franchi L, Drescher D. Effectiveness of maxillary protraction using a hybrid hyrax-facemask combination: a controlled clinical study. *Angle Orthod* 2015;85:764-70.
28. Masucci C, Franchi L, Giuntini V, Defraia E. Short-term effects of a modified Alt-RAMEC protocol for early treatment of Class III malocclusion: a controlled study. *Orthod Craniofac Res* 2014;17:259-69.
29. Slakter MJ, Albino JE, Fox RN, Lewis EA. Reliability and stability of the orthodontic patient cooperation scale. *Am J Orthod* 1980;78:559-63.
30. Schott TC, Göz G. Wearing times of orthodontic devices as measured by the TheraMon® microsensor. *J Orofac Orthop* 2011;72:103-10.
31. Schott TC, Ludwig B. Microelectronic wear-time documentation of removable orthodontic devices detects heterogeneous wear behavior and individualizes treatment planning. *Am J Orthod Dentofacial Orthop* 2014;146:155-60.
32. Tsomos G, Ludwig B, Grossen J, Pazera P, Gkantidis N. Objective assessment of patient compliance with removable orthodontic appliances: a cross-sectional cohort study. *Angle Orthod* 2013;84:56-61.