

Protocols for Combining the Beneslider with Lingual Appliances in Class II Treatment

BENEDICT WILMES, DMD, MSD, PHD
JULIA NEUSCHULZ, DMD, MSD
MITRA SAFFAR, DMD, MSD
BERT BRAUMANN, DMD, MSD, PHD
DIETER DRESCHER, DMD, PHD

Over the past few years, a number of skeletally anchored distalization mechanics have been introduced using various insertion sites and protocols for mini-implants. While the retromolar region has proven unsuitable for mini-implant insertion because of its poor bone quality and thick soft tissue,¹ the alveolar process also seems inappropriate for anchorage of molar distalization, since the mini-implants will be in the path of the moving teeth and high failure rates have been reported.² The anterior palate appears to be the best mini-implant insertion site for distalization of upper molars, with the advantages of good bone quality, a thin attached mucosa, no risk of tooth injury, and a high success rate.^{1,2} Furthermore, palatal mini-implants are not in the way of moving teeth, even with the premolars following the molars distally due to the pull of interdental fibers.

The Beneslider* (Fig. 1) is a distalization appliance anchored by one or two coupled mini-implants in the anterior palate; exchangeable abutments allow a stable and safe connection between the mini-implants and the distalization mechanics.³⁻⁸ When used with lingual brackets, the Beneslider is attached to lingual sheaths on the molars—the same as for a transpalatal bar or Quad Helix,** or the customized molar-band sheaths available with lingual appliance systems

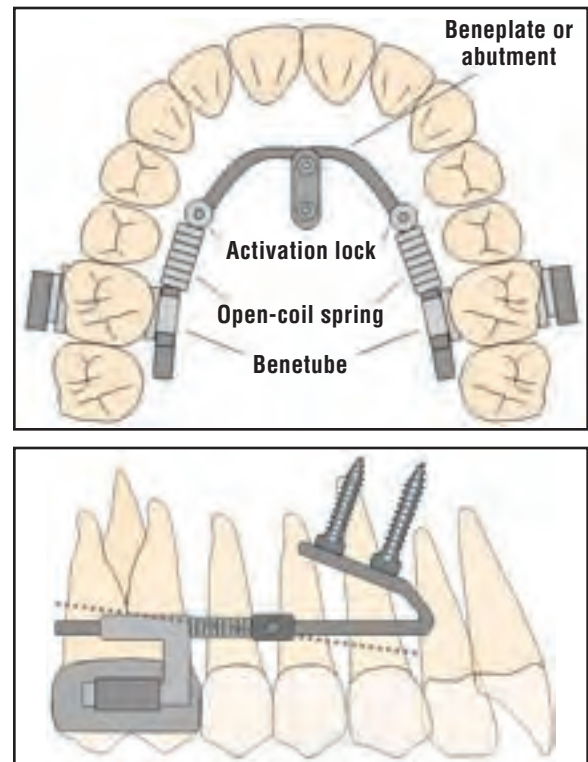


Fig. 1 Beneslider* palatally anchored distalization appliance with Beneplate,* sliding activation locks, and open-coil springs; .043" stainless steel guide wire can be angulated for simultaneous vertical movements (dotted line).



Dr. Wilmes



Dr. Neuschulz



Dr. Saffar



Dr. Braumann



Dr. Drescher

Dr. Wilmes is a Professor and Dr. Drescher is Professor and Head, Department of Orthodontics, University of Düsseldorf, Moorenstrasse 5, 40225 Düsseldorf, Germany. Dr. Wilmes is also a Visiting Professor, Department of Orthodontics, University of Alabama at Birmingham School of Dentistry, and the developer of the Benefit system. Drs. Neuschulz and Saffar are consultants and Dr. Braumann is Professor and Head, Department of Orthodontics, University of Cologne, Cologne, Germany. E-mail Dr. Wilmes at: wilmes@med.uni-duesseldorf.de.

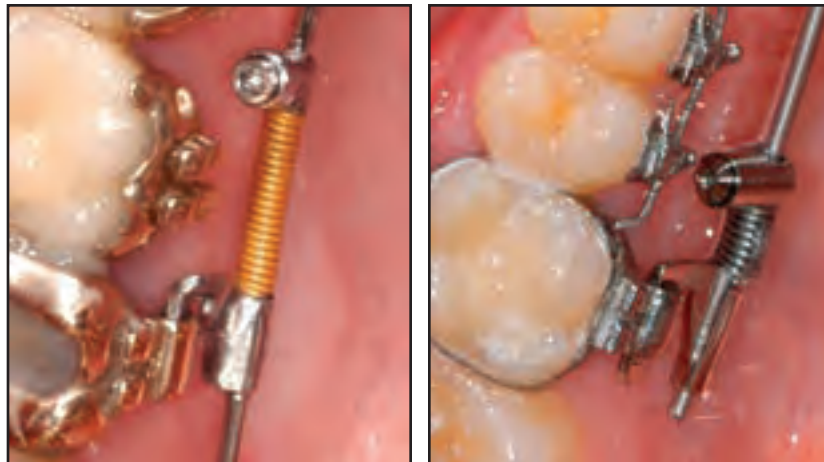


Fig. 2 Beneslider attached to palatal sheaths used with Incognito*** (left) and Ormco 7th-generation† lingual systems.

(Fig. 2). The distalization force is delivered by two springs (240g in children, 500g in adults⁶), activated by two sliding locks that push the Beneslider* distally.

The Beneslider can be installed without welding or soldering, so it can be placed directly in the mouth without the need for impressions. To save chairtime, the Beneslider can also be adapted on a plaster cast made with impression caps over the mini-implants. Follow-up visits are scheduled every four to six weeks. After distalization is complete, the Beneslider is left in place to provide molar anchorage during retraction of the anterior teeth on straight wires. Treatment can be finished

with buccal brackets,^{6,7} aligners,⁸ or, as described in this article, lingual brackets. Since the buccal teeth generally migrate distally during molar distalization, however, an indirect-bonding tray produced from the impression taken before distalization would not fit correctly. The same situation would occur with customized indirect buccal

*PSM Medical Solutions, Tuttlingen, Germany; www.psm.ms. Distributed in the U.S. by PSM North America, Indio, CA; www.psm-na.us.

**Rocky Mountain Orthodontics, Denver, CO; www.rmortho.com.

***Trademark of 3M Unitek, Monrovia, CA; www.3Munitek.com.

†Ormco Corporation, Orange, CA; www.ormco.com.

Bond First	Distalize First
First appointment: Take impression for customized appliance	First appointment: Insert mini-implants (using impression if desired)
Wait for appliance delivery	Install Beneslider
Second appointment: Insert mini-implants (using impression if desired)	Distalization phase
Bond brackets and band molars	Post-distalization: Take impression for customized appliance
Install Beneslider	Wait for appliance delivery
Distalization phase	Bond brackets
Alignment phase	Alignment phase
Retraction phase	Retraction phase

Fig. 3 Beneslider protocols for cases with severe upper crowding.

bonding, as for the Insignia† appliance. To avoid this problem, several different approaches are suggested here, depending on the severity of upper-arch crowding.

Severe Upper Crowding (Fig. 3)

Bond-First Method

In this method, the impression for the customized appliance is taken before molar distalization (see Case 1). Once the appliance has been manufactured, the Beneslider appliance and lingual brackets are placed at the same appointment. The first leveling wire is not inserted until enough space has been gained, thus avoiding over-protrusion. Brackets should be ligated with stainless steel wires during this phase in case of accidental debonding.

Distalize-First Method

Treatment starts with only the Beneslider in place. A precise impression for lingual appliances is taken after the distalization phase, requiring removal and reinsertion of the Beneslider. A vacuum-formed stent can help maintain the correction

and stabilize the teeth until the customized bonding tray is delivered.

Mild Upper Crowding

If the crowding is not too severe, the Beneslider can be inserted during or after leveling. Molar distalization can be carried out simultaneously (see Case 2), although this approach may increase frictional resistance.

Case 1

A 31-year-old male presented with asymmetrical mesial migration of the upper left dentition, which had resulted in severe upper anterior crowding and a shifted midline (Fig. 4). The occlusion was a full-cusp Class II on the left side. Because the patient requested “invisible” orthodontic treatment without extractions, the treatment plan called for unilateral distalization with the Beneslider in combination with Incognito*** appliances, using the bond-first method.

After lingual brackets were bonded with the

***Trademark of 3M Unitek, Monrovia, CA; www.3Munitek.com.

†Ormco Corporation, Orange, CA; www.ormco.com.

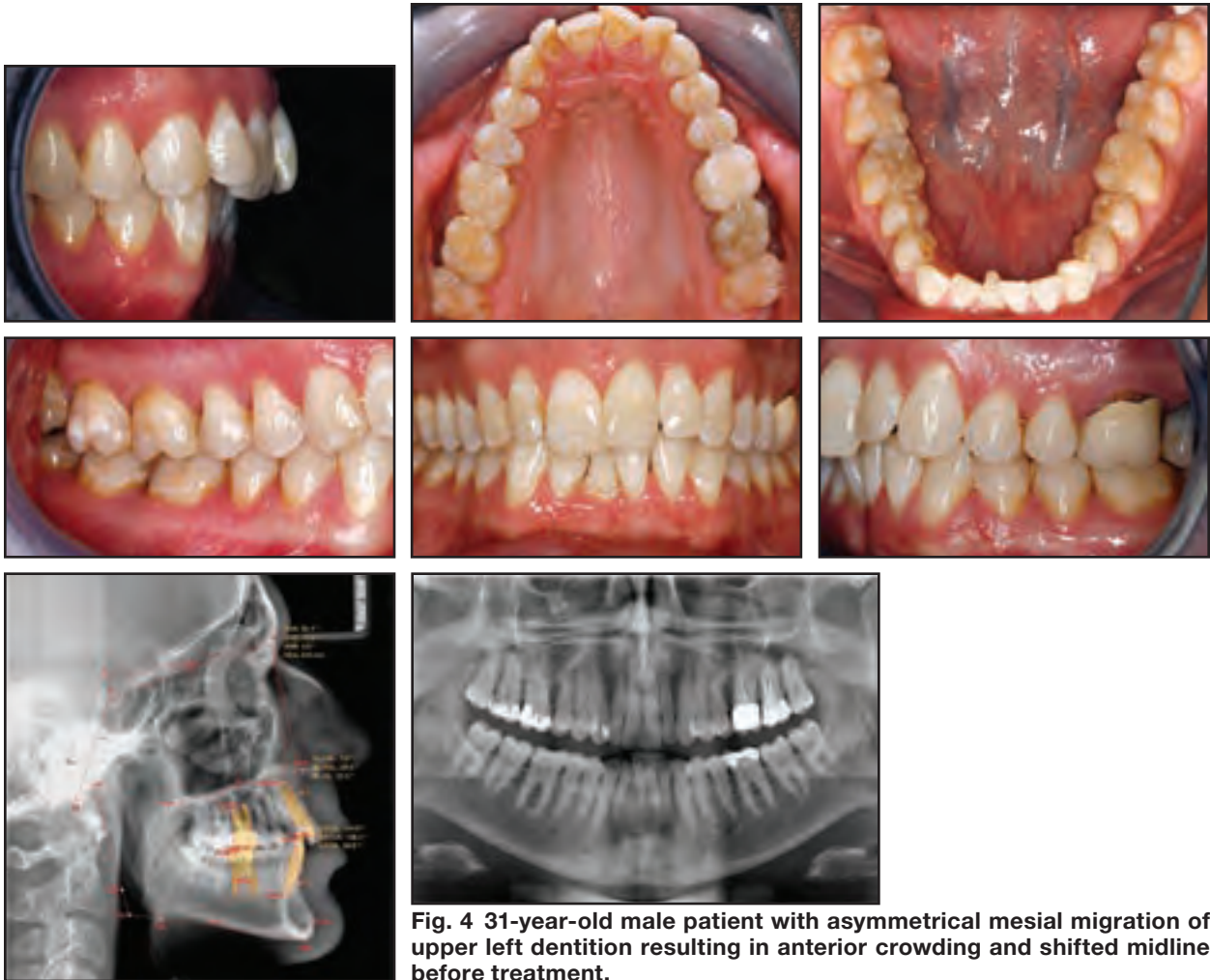


Fig. 4 31-year-old male patient with asymmetrical mesial migration of upper left dentition resulting in anterior crowding and shifted midline before treatment.

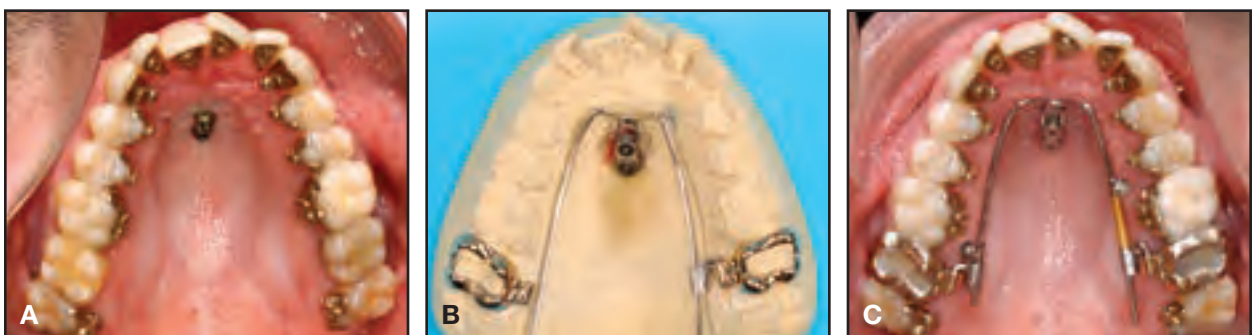

Fig. 5 Case 1. A. After bonding of lingual brackets and insertion of two mini-implants in anterior palate. B. Molar bands with Incognito*** palatal sheaths and Beneplate with .043" wire adapted on plaster cast. C. BeneSlider in place, activated in upper left quadrant and passive in upper right.

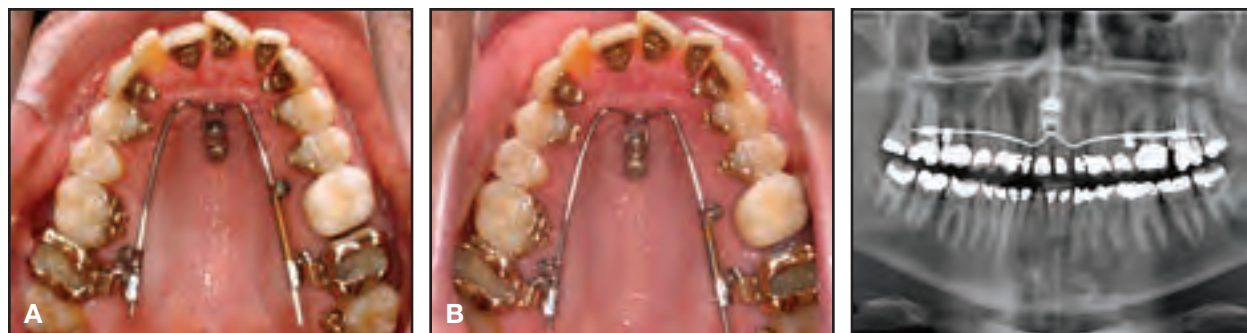

Fig. 6 Case 1. A. After three months of unilateral distalization. **B.** Bodily distalization of upper left second molar apparent after another three months.

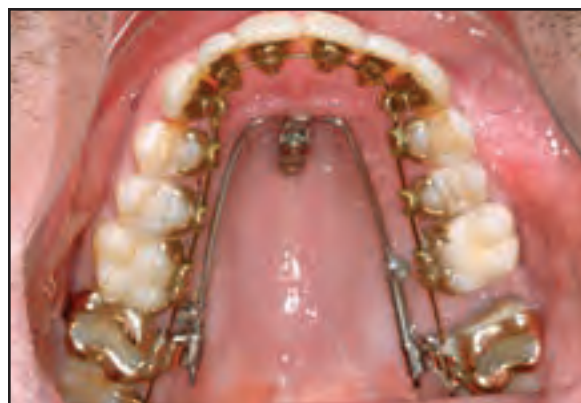

Fig. 7 Case 1. Completion of second-molar distalization and leveling after 11 months of Beneslider use.

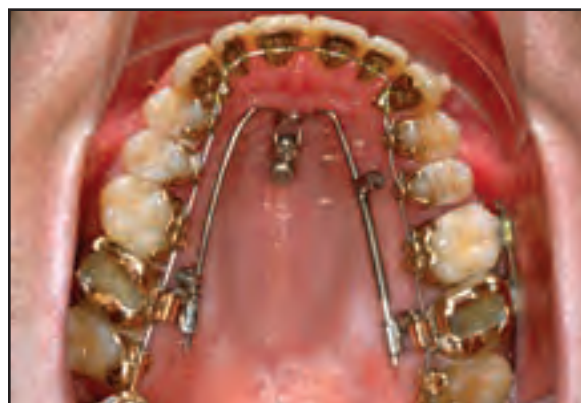

Fig. 8 Case 1. Beneslider left in place as anchorage for retraction of first molar, premolars, and anterior teeth, with additional tube bonded to upright upper left third molar.

customized indirect tray, two Benefit* mini-implants were inserted in the anterior palate (2mm × 11mm, in the area of the third palatal ruga, and 2mm × 9mm, about 8mm distal to the first implant, Fig. 5A). To save some chairtime, an impression was taken and the Beneslider was adapted on the plaster cast. Incognito palatal sheaths were used for a stable connection to the molar bands. A Beneplate with an attached .043" wire was adapted to the palatal slope (Fig. 5B), and the Beneslider was placed and activated with a 500g nickel titanium open-coil spring on the left side. The right side of the appliance was left passive (Fig. 5C).

The first leveling archwire was inserted three months later, after a small space had been opened between the upper left first and second molars (Fig. 6A). After six months of distalization, the space between the upper left molars had increased by 2-3mm, and the panoramic x-ray confirmed bodily distalization of the upper left second molar (Fig. 6B). Molar distalization and leveling were completed in 11 months of treatment (Fig. 7).

The Beneslider was maintained as posterior anchorage for retraction of the first molar, premolars, and anterior teeth (Fig. 8). Retraction and finishing took another six months, and a Class I occlusion was achieved after a total 17 months of treatment (Fig. 9).

*PSM Medical Solutions, Tuttlingen, Germany; www.psm.ms. Distributed in the U.S. by PSM North America, Indio, CA; www.psm-na.us.

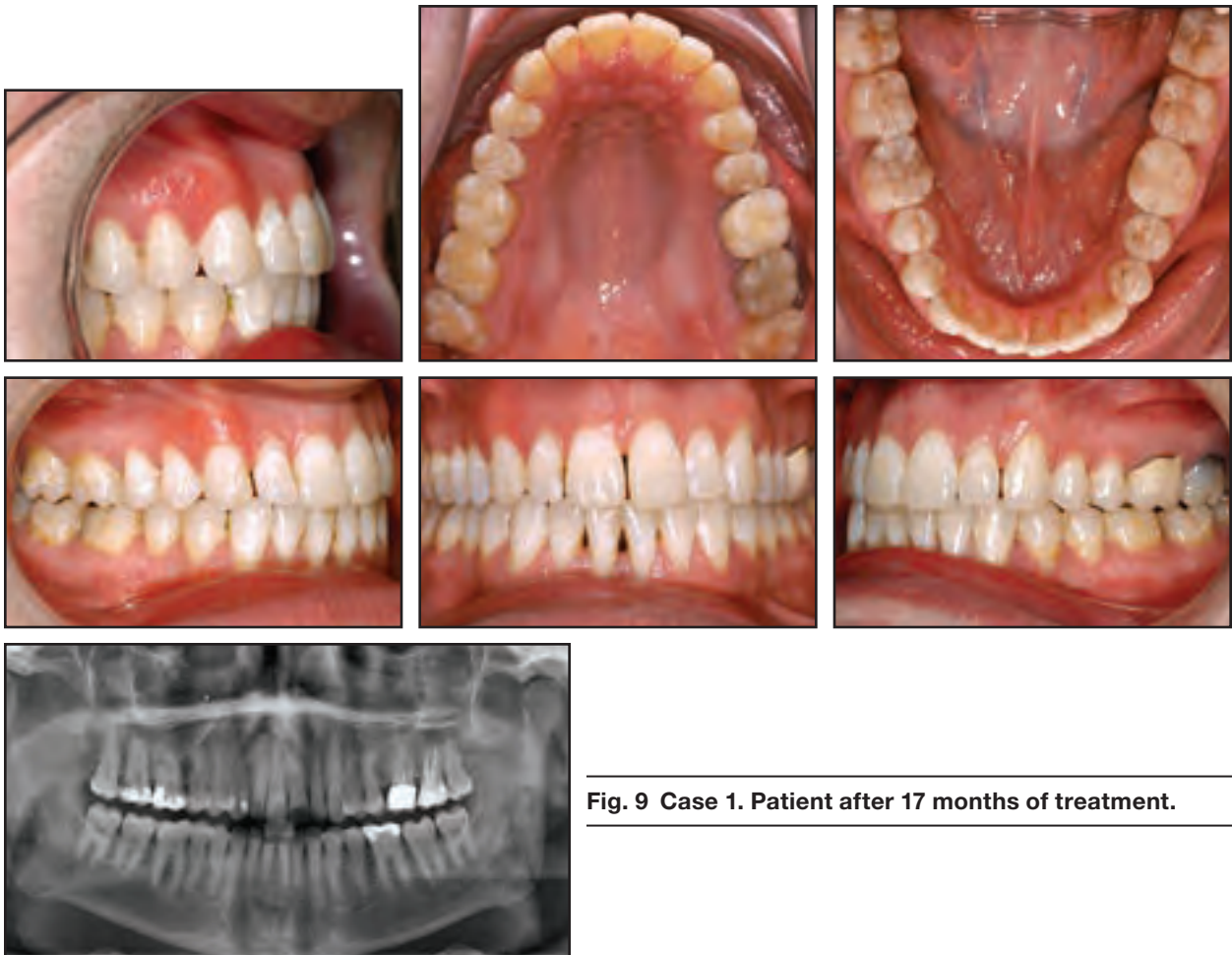


Fig. 9 Case 1. Patient after 17 months of treatment.

Case 2

A 38-year-old female presented with a skeletal Class II malocclusion combined with an anterior open bite (Fig. 10). To resolve the severe skeletal discrepancy, a bimaxillary osteotomy was recommended. The patient declined surgery, however, and asked for an alternative treatment plan involving “invisible” appliances in the upper arch. Because of the proclination of the upper incisors and the moderate degree of upper crowding, we proposed simultaneous distalization of the upper dentition with the Beneslider and intrusion of the upper molars.

Treatment began with bonding of Incognito lingual brackets, placement of a leveling archwire, and installation of the Beneslider. The guide wires of the Beneslider were angulated to produce both distalization and molar intrusion (Figs. 1,11).

The leveling phase was completed in three months (Fig. 12A). Another three months later, the molars had been sufficiently distalized and intruded (Fig. 12B); the retraction phase was started three weeks after that (Fig. 12C). Normal overjet and overbite were achieved after a total 13 months of treatment (Fig. 13A). Due to a bowing effect during space closure, however, the upper left second molar showed a tendency toward pal-

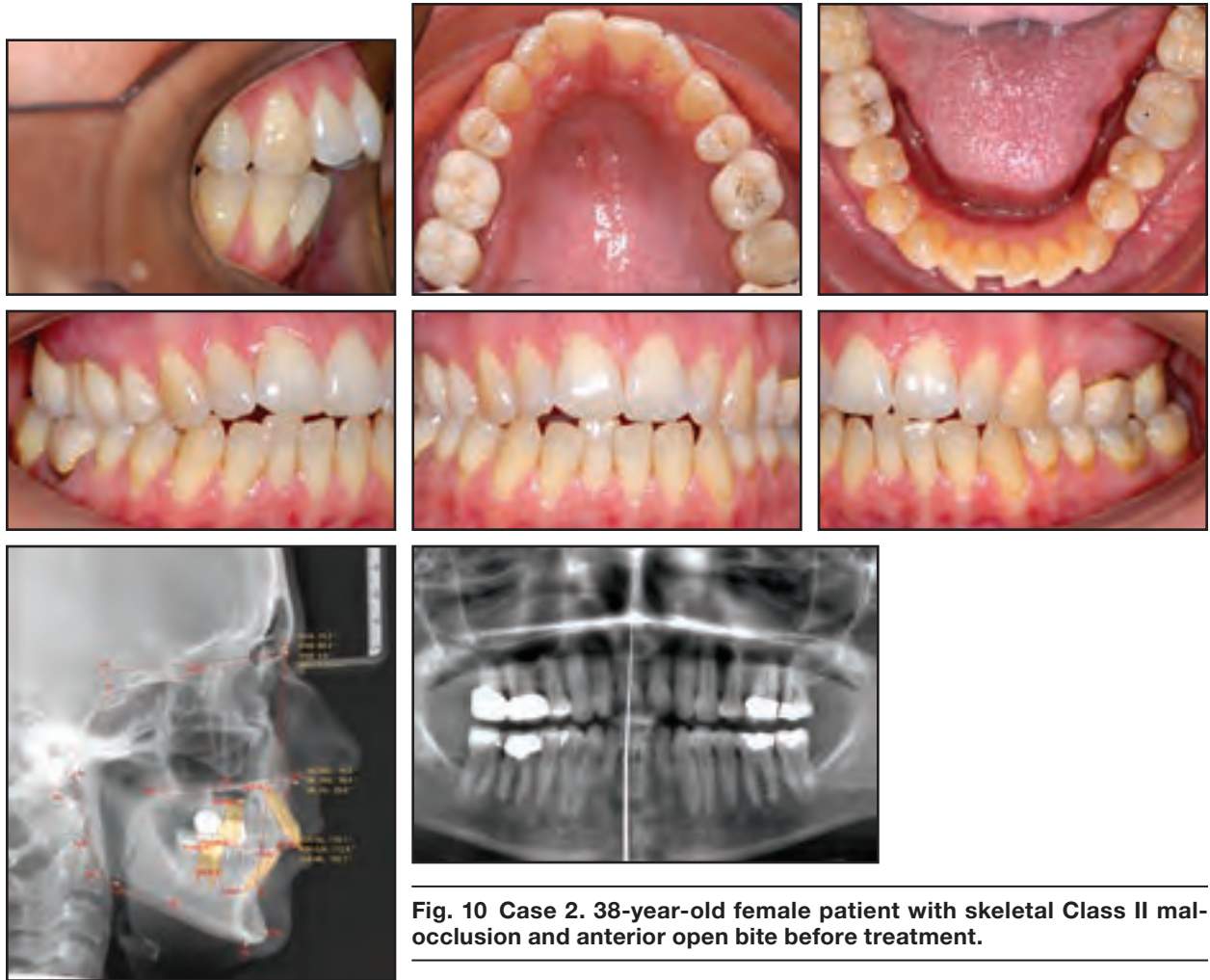


Fig. 10 Case 2. 38-year-old female patient with skeletal Class II malocclusion and anterior open bite before treatment.

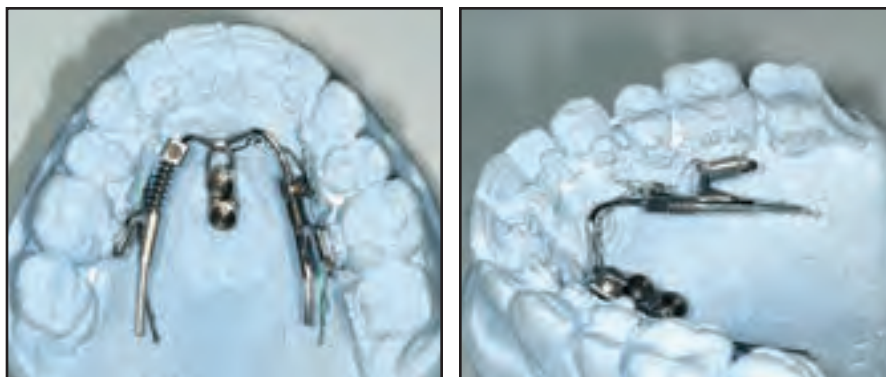


Fig. 11 Case 2. Beneslider guide wires angulated for simultaneous distalization and molar intrusion.

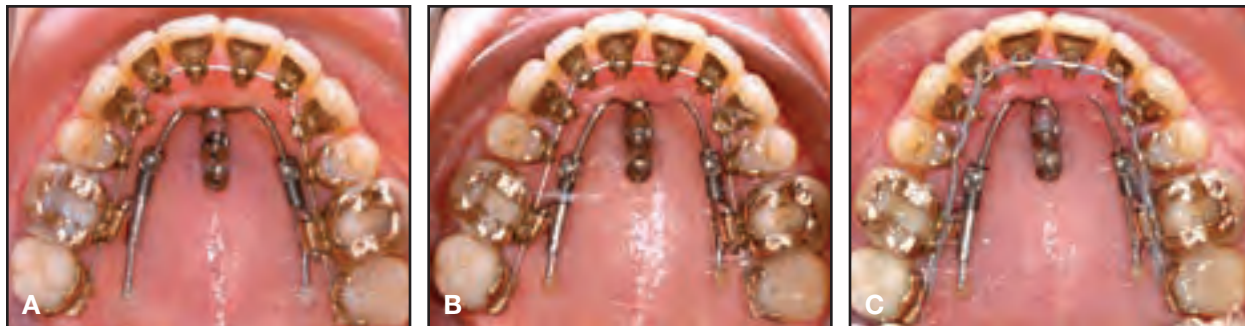

Fig. 12 Case 2. A. After three months of leveling. B. Molars sufficiently distalized and intruded after six months of treatment. C. Three weeks later, elastic chain applied for premolar and anterior retraction.

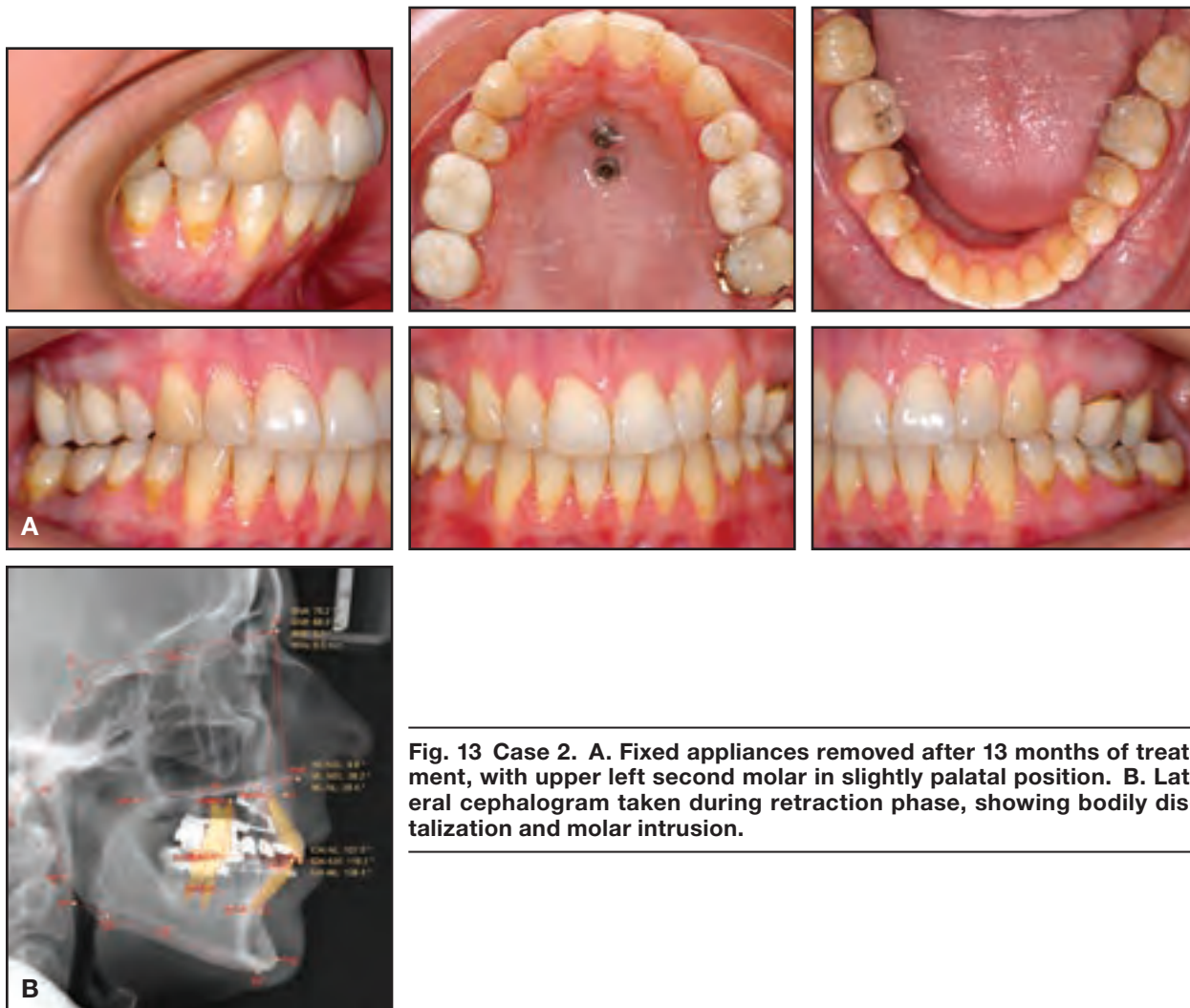


Fig. 13 Case 2. A. Fixed appliances removed after 13 months of treatment, with upper left second molar in slightly palatal position. B. Lateral cephalogram taken during retraction phase, showing bodily distalization and molar intrusion.

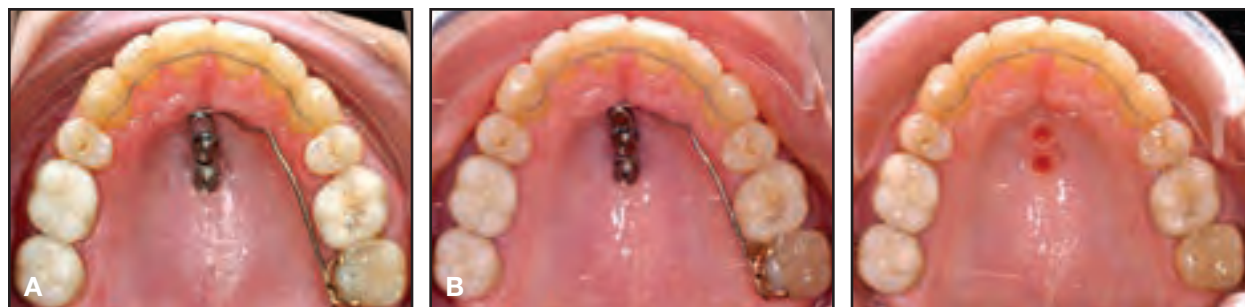

Fig. 14 Case 2. A. Beneplate with .032" wire used to move upper left second molar buccally. B. Beneplate and mini-implants removed two months later, with second molar in proper position

atal crossbite (Fig. 13B). The molar bracket and mini-implants were left in place, and a Beneplate with an attached .032" wire was used for two months to move the upper left second molar buccally (Fig. 14A). This multipurpose application of the Beneslider was made possible by the use of mini-implants with exchangeable abutments.^{9,10} The mini-implants were unscrewed at the end of treatment without anesthesia (Fig. 14B).

Discussion

Distalizing mechanics based on conventional anchorage often result in unwanted distal molar tipping, which may be prone to relapse. Conversely, the Beneslider produces almost bodily distalization of the molars without clinically significant tipping: Wilmes and Drescher reported about 2° of upper molar tipping,⁷ and Nienkemper and colleagues found a mean 1.5° of molar tipping in 51 patients treated with Benesliders.⁶ Pendulum-based distalization mechanics have been associated with much greater molar tipping.¹¹

With adequate bone volume and thin soft tissue available for successful mini-implant insertion as far as 3mm lateral to the midpalatal suture, the failure rate of miniscrews placed in the anterior palate has been extremely low.^{1,2,6,12,13} In addition, because there are no roots, blood vessels, or nerves in the area, there is little risk of complications. Palatal mini-implants should generally be left in place until treatment is completely finished, since they can be used for subsequent tooth movements and mechanics.¹⁰

REFERENCES

- Ludwig, B.; Glasl, B.; Bowman, S.J.; Wilmes, B.; Kinzinger, G.S.; and Lisson, J.A.: Anatomical guidelines for miniscrew insertion: Palatal sites, *J. Clin. Orthod.* 45:433-441, 2011.
- Lim, H.J.; Choi, Y.J.; Evans, C.A.; and Hwang, H.S.: Predictors of initial stability of orthodontic miniscrew implants, *Eur. J. Orthod.* 33:528-532, 2011.
- Wilmes, B.: Fields of application of mini-implants, in *Innovative Anchorage Concepts: Mini-Implants in Orthodontics*, ed. B. Ludwig, S. Baumgaertel, and S.J. Bowman, Berlin, Quintessence, 2008.
- Wilmes, B. and Drescher, D.: A miniscrew system with interchangeable abutments, *J. Clin. Orthod.* 42:574-580, 2008.
- Wilmes, B.; Drescher, D.; and Nienkemper, M.: A miniplate system for improved stability of skeletal anchorage, *J. Clin. Orthod.* 43:494-501, 2009.
- Nienkemper, M.; Wilmes, B.; Pauls, A.; Yamaguchi, S.; and Drescher, D.: Treatment efficiency of mini-implant-borne distalization depending on age and second-molar eruption, *J. Orofac. Orthop.* 75:118-132, 2014.
- Wilmes, B. and Drescher, D.: Application and effectiveness of the Beneslider: A device to move molars distally, *World J. Orthod.* 11:331-340, 2010.
- Wilmes, B.; Nienkemper, M.; Ludwig, B.; Kau, C.H.; Pauls, A.; and Drescher, D.: Esthetic Class II treatment with the Beneslider and aligners, *J. Clin. Orthod.* 46:390-398, 2012.
- Nienkemper, M.; Wilmes, B.; Pauls, A.; and Drescher, D.: Multipurpose use of orthodontic mini-implants to achieve different treatment goals, *J. Orofac. Orthop.* 73:467-476, 2012.
- Nienkemper, M.; Pauls, A.; Ludwig, B.; Wilmes, B.; and Drescher, D.: Multifunctional use of palatal mini-implants, *J. Clin. Orthod.* 46:679-686, 2012.
- Kinzinger, G.S.; Eren, M.; and Diedrich, P.R.: Treatment effects of intraoral appliances with conventional anchorage designs for non-compliance maxillary molar distalization: A literature review, *Eur. J. Orthod.* 30:558-571, 2008.
- Karagkiolidou, A.; Ludwig, B.; Pazera, P.; Gkantidis, N.; Pandis, N.; and Katsaros, C.: Survival of palatal miniscrews used for orthodontic appliance anchorage: A retrospective cohort study, *Am. J. Orthod.* 143:767-772, 2013.
- Bernhart, T.; Freudenthaler, J.; Dortbudak, O.; Bantleon, H.P.; and Watzek, G.: Short epithetic implants for orthodontic anchorage in the paramedian region of the palate: A clinical study, *Clin. Oral Impl. Res.* 12:624-631, 2001.