



Experts Corner

## “Appliance First” or “Bone First” for miniscrew assisted rapid palatal expansion?

Benedict Wilmes

Department of Orthodontics, University of Duesseldorf, Duesseldorf, Germany.



**\*Corresponding author:**

Benedict Wilmes,  
Department of Orthodontics,  
University of Duesseldorf,  
Duesseldorf, Germany.

wilmes@med.uni-duesseldorf.de

Received : 30 March 2022


Accepted : 30 March 2022

Published : 19 April 2022

**DOI**

10.25259/APOS\_57\_2022

**Quick Response Code:**



Rapid palatal or maxillary expansion (RME) is considered the optimal procedure to achieve a skeletal widening of the maxilla.<sup>[1,2]</sup> Since the anchor teeth distribute the forces to the bony structures through the anchor teeth, distribution of the forces to as many teeth as possible and completion of root growth are considered essential. However, side effects, for example, tipping teeth, root resorption, decrease in buccal bone thickness or dehiscence, and loss of marginal bone height resulting in gingival recessions may occur.<sup>[3-6]</sup>

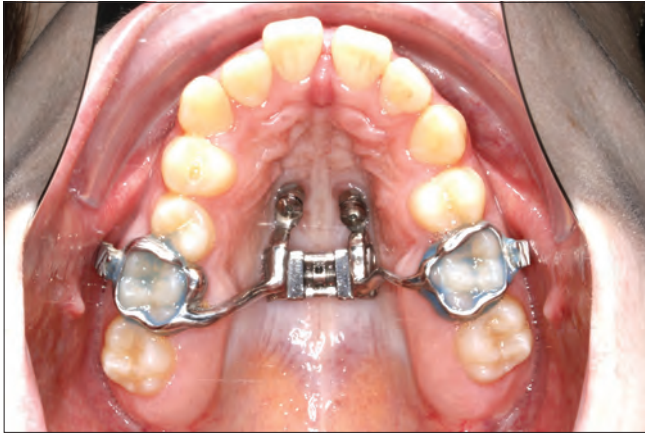More recently, mini-implants to share the load of the expansion with the anchorage teeth to reduce or eliminate the unwanted dental side effects were used. Wilmes *et al.* introduced the Hybrid Hyrax expander in 2007 using two mini-implants in the anterior palate and two (deciduous) molars [Figure 1].<sup>[7-10]</sup> Similar hybrid expanders were published in the following years by Garib *et al.*<sup>[11]</sup> in 2008, Lee *et al.*<sup>[12]</sup> in 2010, and Moon *et al.*<sup>[13]</sup> in 2015 called MSE [Figure 2, Mini-Screw Assisted Expansion]. Mini-implant-supported expanders with additional buccal extensions [Figure 3] can also be used very successfully to treat growing Class III patients<sup>[14-21]</sup> allowing skeletal maxillary protraction without the common dental side effects.<sup>[13,16,17,22]</sup> In addition, alternating expansion and constriction of the maxilla Alt-RAMEC<sup>[21,23]</sup> over 9 weeks can enhance the response of the maxilla to the protraction forces and offer a good response in children with more sutural maturation.<sup>[24-26]</sup>

For the stability and predictability of the mini-implants (TADs), we need to place them in the areas with the best cortical bone quality. Several CBCT studies have shown that this is in the anterior palate along an area designated as the T-Zone [Figure 4].<sup>[27-29]</sup> In the conventional Hybrid Hyrax, the mini-implants are placed paramedian in the anterior palate in the T-Zone. An impression or scan is taken and sent to a laboratory to manufacture the appliance, which is then fitted in a subsequent appointment. More recently, these appliances can be manufactured using selective laser melting procedures.<sup>[30]</sup> The available printing metal powders provide a high rigidity of the appliance, which seems very important, especially for expansion appliances. Furthermore, this process can be made more efficient using CAD/CAM manufactured insertion guides, which facilitate a safe and precise insertion of mini-implants in the anterior palate in the areas of the best bone [Figure 5]. Furthermore, these insertion guides allow for the insertion of mini-implants and installing the appliance in a single appointment.<sup>[31,32]</sup>

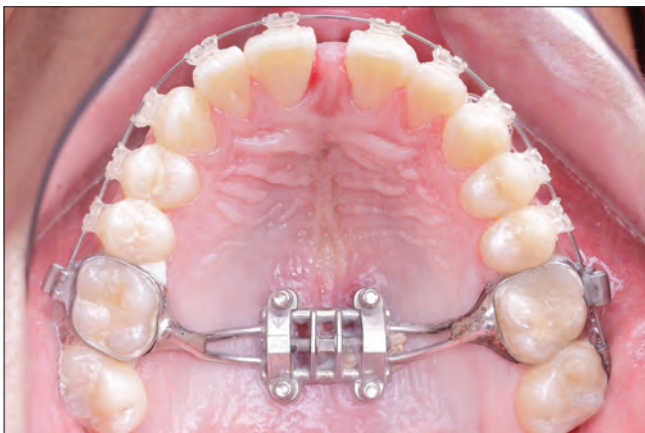In both of the above approaches, with impression/scan and insertion guides, mini-implants are inserted first, and the appliance is installed afterward. This method can be called “TADs

This is an open-access article distributed under the terms of the Creative Commons Attribution-Non Commercial-Share Alike 4.0 License, which allows others to remix, transform, and build upon the work non-commercially, as long as the author is credited and the new creations are licensed under the identical terms.

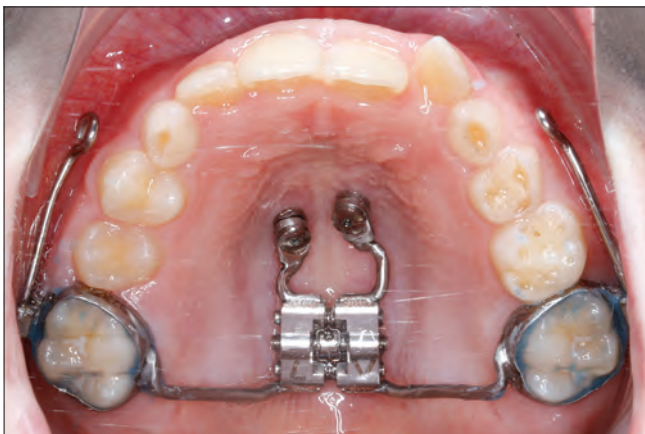
©2022 Published by Scientific Scholar on behalf of APOS Trends in Orthodontics



**Figure 1:** Principle of the Hybrid Hyrax: two mini-implants in the anterior palate to support RME: “TADs First” or “Bone First.”



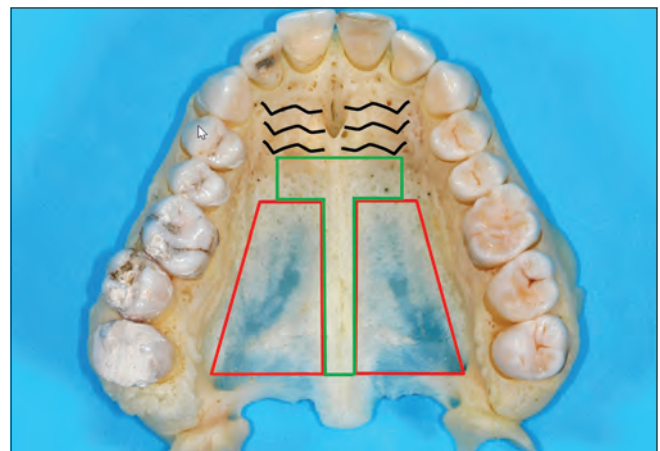
**Figure 2:** Principle of the MSE appliance: Four mini-implants in the posterior palate to support RME: “Appliance First” (Dr. Miguel Hirschhaut).



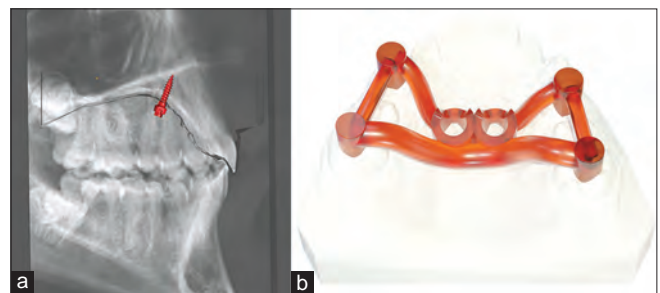**Figure 3:** Buccal segmental hooks for maxillary protraction with a facemask.

First.” A disadvantage of this “TADs First” procedure is the need for two appointments: One to insert the TADs and the second to cement the appliances. Using the insertion guide eliminates this issue, however. Second, the appliances may not fit if there are inaccuracies during the manufacturing process. This problem may also occur when using an insertion guide, especially if there is a change due to tooth eruption or movement from the original scan to the insertion appointment.

As an alternative to the TADs First concept, it was proposed to insert the expansion appliance first and 2–4 mini-implants afterward. For example, with the MSE.<sup>[33]</sup> This protocol can be called “Appliance First.” A disadvantage of the conventional appliance first method is choosing the placement site for the mini-implant freely based on bone quality. The prefabricated nature of the appliance restricts the placement site of the mini-implants. It may be possible to shift the mechanisms forward or backward to allow the channels to line up with an area of good bone. Unfortunately, it is unlikely that all



**Figure 4:** Picture of a maxilla of a cadaver: Recommended insertion site (T-Zone) posterior from the rugae. The bone is usually very thin in the posterior and lateral areas.



**Figure 5:** Guided insertion of palatal TADs: (a) Virtual positioning after superimposition of an upper scan and a cephalogram. (b) Design of a CAD-CAM insertion guide.

2–to 4 mini-implants will be consistently in the best bone quality areas. This problem is especially pertinent in the posterior molar area where the bone height is only 1–2 mm in paramedian sites.<sup>[27,28]</sup> In addition, the connection between the expander and the mini-implants in those appliances is not rigid and angularly stable. As a consequence, mini-implants have some play with the expander and will tip as soon as the expander is activated.<sup>[34]</sup>

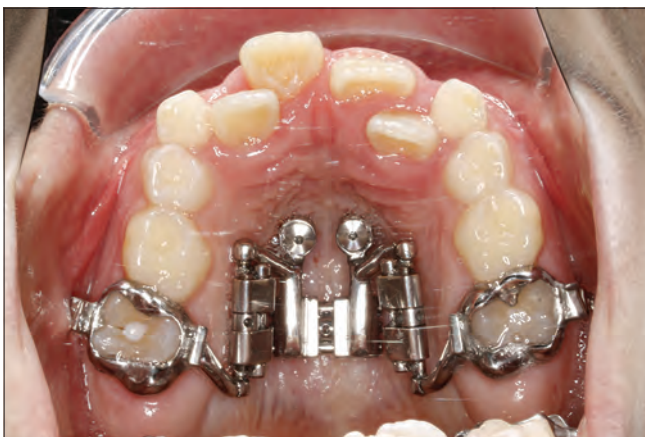## PROS AND CONS OF “APPLIANCE FIRST” METHOD VERSUS “TADS FIRST” METHOD

### Advantages of the “Appliance First” method (MSE)

- Mini-implant insertion and installation of the appliance in just one appointment
- No impression/scan is needed after mini-implant insertion
- No risk of misfitting the appliance and the mini-implants.

### Advantages of the “TADs First” method (hybrid hyrax)

- The appliance can be removed and re-installed easily, for example, for modifications or repairs
- Rigid and stable connection between the mini-implants and the expansion appliance
- The customized design allows total freedom in selecting the mini-implant sites to utilize the best available bone. As a consequence, the “TADs First” approach can also be called “Bone First”
- Mini-implants can be used to anchor more than one appliance, for example in the first step for RME and a second step for molar distalization<sup>[35]</sup>
- Due to free customization, multipurpose appliances such as the Hybrid Hyrax Distalizer<sup>[36]</sup> for RME and a subsequent molar distalization can be designed [Figure 6].



**Figure 6:** Miniscrew assisted rapid palatal expansion and subsequent distalization in one appliance: Hybrid Hyrax Distalizer.

### Declaration of patient consent

Patient’s consent not required as there are no patients in this study.

### Financial support and sponsorship

Nil.

### Conflicts of interest

There are no conflicts of interest.

### REFERENCES

1. Kurokawa J, Berglund L. Longitudinal study and cost-benefit analysis of the effect of early treatment of posterior cross-bites in the primary dentition. *Eur J Orthod* 1992;14:173-9.
2. Camacho M, Chang ET, Song SA, Abdullatif J, Zaghi S, Pirelli P, et al. Rapid maxillary expansion for pediatric obstructive sleep apnea: A systematic review and meta-analysis. *Laryngoscope* 2017;127:1712-9.
3. Garib DG, Henriques JF, Janson G, de Freitas MR, Fernandes AY. Periodontal effects of rapid maxillary expansion with tooth-tissue-borne and tooth-borne expanders: A computed tomography evaluation. *Am J Orthod Dentofacial Orthop* 2006;129:749-58.
4. Schuster G, Borel-Scherf I, Schopf PM. Frequency of and complications in the use of RPE appliances--results of a survey in the Federal State of Hesse, Germany. *J Orofac Orthop* 2005;66:148-61.
5. Erverdi N, Okar I, Kucukkeles N, Arbak S. A comparison of two different rapid palatal expansion techniques from the point of root resorption. *Am J Orthod Dentofacial Orthop* 1994;106:47-51.
6. Akyalcin S, Alexander SP, Silva RM, English JD. Evaluation of three-dimensional root surface changes and resorption following rapid maxillary expansion: A cone beam computed tomography investigation. *Orthod Craniofac Res* 2015;18 Suppl 1:117-26.
7. Wilmes B, Drescher D. A miniscrew system with interchangeable abutments. *J Clin Orthod* 2008;42:574-580; quiz 595.
8. Wilmes B. Fields of application of mini-implants. In: Ludwig B, Baumgaertel S, Bowman J, editors. *Innovative Anchorage Concepts. Mini-Implants in Orthodontics*. Berlin, New York: Quintessenz; 2008.
9. Wilmes B. Anwendungsgebiete von mini-implantaten. In: Ludwig B, editor. *Mini-Implantate in der Kieferorthopädie Innovative Verankerungskonzepte*. Berlin: Quintessenz; 2007. p. 89-120.
10. Wilmes B, Nienkemper M, Drescher D. Application and effectiveness of a mini-implant and tooth-borne rapid palatal expansion device: The hybrid hyrax. *World J Orthod* 2010;11:323-30.
11. Garib DG, Navarro R, Francischone CE, Oltramari PV. Rapid maxillary expansion using palatal implants. *J Clin Orthod* 2008;42:665-71.



12. Lee KJ, Park YC, Park JY, Hwang WS. Miniscrew-assisted nonsurgical palatal expansion before orthognathic surgery for a patient with severe mandibular prognathism. *Am J Orthod Dentofacial Orthop* 2010;137:830-9.
13. Moon W, Wu KW, MacGinnis M, Sung J, Chu H, Youssef G, *et al.* The efficacy of maxillary protraction protocols with the micro-implant-assisted rapid palatal expander (MARPE) and the novel N2 mini-implant-a finite element study. *Prog Orthod* 2015;16:16.
14. Wilmes B, Nienkemper M, Ludwig B, Kau CH, Drescher D. Early Class III treatment with a hybrid hyrax-mentoplate combination. *J Clin Orthod* 2011;45:15-21; quiz 39.
15. Stocker B, Willmann JH, Wilmes B, Vasudavan S, Drescher D. Wear-time recording during early Class III facemask treatment using TheraMon chip technology. *Am J Orthod Dentofacial Orthop* 2016;150:533-40.
16. Nienkemper M, Wilmes B, Franchi L, Drescher D. Effectiveness of maxillary protraction using a hybrid hyrax-facemask combination: A controlled clinical study. *Angle Orthod* 2015;85:764-70.
17. Ngan P, Wilmes B, Drescher D, Martin C, Weaver B, Gunel E. Comparison of two maxillary protraction protocols: Toothborne versus bone-anchored protraction facemask treatment. *Prog Orthod* 2015;16:26.
18. Wilmes B, Ngan P, Liou EJ, Franchi L, Drescher D. Early Class III facemask treatment with the hybrid hyrax and Alt-RAMEC protocol. *J Clin Orthod* 2014;48:84-93.
19. Baccetti T, McGill JS, Franchi L, McNamara JA Jr., Tollaro I. Skeletal effects of early treatment of Class III malocclusion with maxillary expansion and face-mask therapy. *Am J Orthod Dentofacial Orthop* 1998;113:333-43.
20. Jager A, Braumann B, Kim C, Wahner S. Skeletal and dental effects of maxillary protraction in patients with angle Class III malocclusion. A meta-analysis. *J Orofac Orthop* 2001;62:275-284.
21. Foersch M, Jacobs C, Wriedt S, Hechtner M, Wehrbein H. Effectiveness of maxillary protraction using facemask with or without maxillary expansion: A systematic review and meta-analysis. *Clin Oral Investig* 2015;19:1181-92.
22. Ngan P, Moon W. Evolution of Class III treatment in orthodontics. *Am J Orthod Dentofacial Orthop* 2015;148:22-36.
23. Liou EJ. Effective maxillary orthopedic protraction for growing Class III patients: A clinical application simulates distraction osteogenesis. *Prog Orthod* 2005;6:154-71.
24. Buyukcavus MH. Alternate rapid maxillary expansion and constriction (Alt-RAMEC) protocol: A comprehensive literature review. *Turk J Orthod* 2019;32:47-51.
25. Franchi L, Baccetti T, Masucci C, Defraia E. Early alt-RAMEC and facial mask protocol in Class III malocclusion. *J Clin Orthod* 2011;45:601-9.
26. Almuzian M, McConnell E, Darendeliler MA, Alharbi F, Mohammed H. The effectiveness of alternating rapid maxillary expansion and constriction combined with maxillary protraction in the treatment of patients with a Class III malocclusion: A systematic review and meta-analysis. *J Orthod* 2018;45:250-9.
27. Becker K, Unland J, Wilmes B, Tarraf NE, Drescher D. Is there an ideal insertion angle and position for orthodontic mini-implants in the anterior palate? A CBCT study in humans. *Am J Orthod Dentofacial Orthop* 2019;156:345-54.
28. Kang S, Lee SJ, Ahn SJ, Heo MS, Kim TW. Bone thickness of the palate for orthodontic mini-implant anchorage in adults. *Am J Orthod Dentofacial Orthop* 2007;131:S74-81.
29. Wilmes B, Ludwig B, Vasudavan S, Nienkemper M, Drescher D. The T-Zone: Median vs. paramedian insertion of palatal mini-implants. *J Clin Orthod* 2016;50:543-51.
30. Graf S, Cornelis MA, Hauber Gameiro G, Cattaneo PM. Computer-aided design and manufacture of hyrax devices: Can we really go digital? *Am J Orthod Dentofacial Orthop* 2017;152:870-4.
31. De Gabriele O, Dallatana G, Riva R, Vasudavan S, Wilmes B. The easy driver for placement of palatal mini-implants and a maxillary expander in a single appointment. *J Clin Orthod* 2017;51:728-37.
32. Wilmes B, Vasudavan S, Drescher D. CAD-CAM-fabricated mini-implant insertion guides for the delivery of a distalization appliance in a single appointment. *Am J Orthod Dentofacial Orthop* 2019;156:148-56.
33. Carlson C, Sung J, McComb RW, Machado AW, Moon W. Microimplant-assisted rapid palatal expansion appliance to orthopedically correct transverse maxillary deficiency in an adult. *Am J Orthod Dentofacial Orthop* 2016;149:716-28.
34. de la Iglesia G, Walter A, de la Iglesia F, Winsauer H, Puigdollers A. Stability of the anterior arm of three different Hyrax hybrid expanders: An *in vitro* study. *Dental Press J Orthod* 2018;23:37-45.
35. Nienkemper M, Pauls A, Ludwig B, Wilmes B, Drescher D. Multifunctional use of palatal mini-implants. *J Clin Orthod* 2012;46:679-86; quiz 703-674.
36. Wilmes B, Ludwig B, Katyal V, Nienkemper M, Rein A, Drescher D. The Hybrid Hyrax Distalizer, a new all-in-one appliance for rapid palatal expansion, early Class III treatment and upper molar distalization. *J Orthod* 2014;41 Suppl 1:S47-53.

**How to cite this article:** Wilmes B. “Appliance First” or “Bone First” for miniscrew assisted rapid palatal expansion? *APOS Trends Orthod* 2022;12:3-6.